

# การเปลี่ยนแปลงเนื้อเยื่อปริทันต์ภายหลังวิธีการรักษาทางทันตกรรมจัดฟันโดยการกรอกระดูกที่บร่วมกับการเสริมกระดูกและคอนเซนเทรตเต็ดโกรทแฟกเตอร์

## Change of periodontal tissue following augmented-corticotomy assisted orthodontics using concentrated growth factor

เกริกวัชร สุริยาอัมพร<sup>1</sup> ทองนารณ คำใจ<sup>2</sup>  
ปวีตรา ไวกษตรกรรม<sup>3</sup> นวพร ฤทธิวิรุฬห์<sup>3</sup> ธนสิน บุญทวีคุณ<sup>3</sup>  
Krerkwachara Suriya-amporn<sup>1</sup> Thongnard Kumchai<sup>2</sup>  
Pavitra Waikasetkorn<sup>3</sup> Nawaporn Ritwiroon<sup>3</sup> Thanasin Boonthavikoon<sup>3</sup>

<sup>1</sup>นักศึกษาหลักสูตรวิทยาศาสตรมหาบัณฑิต <sup>2</sup>รองศาสตราจารย์ <sup>3</sup>อาจารย์ คณะทันตแพทยศาสตร์ มหาวิทยาลัยกรุงเทพมหานคร  
<sup>1</sup>Master's Degree Candidate, <sup>2</sup>Associate professor, <sup>3</sup>Lecturer, Faculty of Dentistry Bangkokthonburi University

### บทคัดย่อ

การใช้คอนเซนเทรตเต็ดโกรทแฟกเตอร์ในกระบวนการกรอกระดูกที่บร่อบรากฟันบร่วมกับการเสริมกระดูกได้รับการพิสูจน์ว่าเป็นกระบวนการที่มีประสิทธิภาพในการเพิ่มความหนาของกระดูกด้านริมฝีปากที่บริเวณกึ่งกลางและบริเวณปลายรากฟัน รวมทั้งสามารถเพิ่มอัตราการเคลื่อนฟันด้วยการจัดฟันภายหลังการผ่าตัด การศึกษานี้เป็นการศึกษาต่อเนื่องโดยมีวัตถุประสงค์เพื่อประเมินสภาวะปริทันต์ภายหลังการใช้คอนเซนเทรตเต็ดโกรทแฟกเตอร์ในกระบวนการกรอกระดูกที่บร่อบรากฟันบร่วมกับการเสริมกระดูกในผู้ใหญ่ที่มารับการจัดฟันในแต่ละช่วงเวลาการรักษา ได้ทำการประเมินสภาวะปริทันต์ของผู้ป่วย 8 ราย ซึ่งเป็นผู้ป่วยผู้ใหญ่และได้รับการรักษาด้วยเทคนิคดังกล่าว โดยใช้ตัวชี้วัดทางคลินิก 5 ตัวชี้วัด ได้แก่ ความลึกของร่องปริทันต์ ระยะรอยต่อเคลือบฟันและเคลือบรากฟันถึงขอบเหงือก การสูญเสียระดับยึดทางคลินิก ความกว้างของเหงือกยึด และการโยกของฟัน ข้อมูลถูกเก็บก่อนการผ่าตัด (T0) ภายหลังการผ่าตัด 6 เดือน (T6) และภายหลังการผ่าตัด 12 เดือน (T12) ผลการศึกษาพบว่า ค่าเฉลี่ยของความลึกร่องปริทันต์ลดลงอย่างมีนัยสำคัญจาก T0-T6 และ T12 ระยะรอยต่อเคลือบฟันและเคลือบรากฟันถึงขอบเหงือกเพิ่มขึ้นอย่างมีนัยสำคัญจาก

Corresponding author: รศ.ทพ.ทองนารณ คำใจ

คณะทันตแพทยศาสตร์ มหาวิทยาลัยกรุงเทพมหานคร  
16/10 ถ.เลียบบคลองทวีวัฒนา แขวงทวีวัฒนา เขตทวีวัฒนา กรุงเทพฯ  
โทร.: 0-2800-6800-5, 08-1881-4481  
E-mail address: thongnard@hotmail.com

Received 10 September 2020; revised 9 November 2020; accepted 26 November 2020

T0-T6 และ T12 การสูญเสียระดับยึดทางคลินิกไม่มีการเปลี่ยนแปลงอย่างมีนัยสำคัญทางสถิติจาก T0-T6 และ T12 ความกว้างของเหงือกยึดเพิ่มขึ้นอย่างมีนัยสำคัญจาก T0-T6 และจากนั้นลดลงอย่างมีนัยสำคัญจาก T6-T12 ความแน่นของฟันลดลงที่ T6, T12 เมื่อเทียบกับ T0 จากผลการศึกษาอาจสรุปได้ว่าการกรอกระดูกที่บรอบรากฟันร่วมกับการเสริมกระดูกและคอนเซนเทรตเต็ทโกรทแฟกเตอร์ส่งผลทั้งเชิงบวกและเชิงลบ กล่าวคือ เทคนิคนี้สามารถลดความลึกร่องปริทันต์ รักษาระดับยึดทางคลินิกและความแน่นของฟันให้อยู่ในระดับปลอดภัย และเพิ่มความกว้างของเหงือกยึดอย่างไรก็ตาม ผลในเชิงลบของเทคนิคนี้คือระยะรอยต่อเคลือบฟันและเคลือบรากฟันถึงขอบเหงือกเพิ่มขึ้น

**คำสำคัญ:** กระบวนการกรอกระดูกที่บรอบรากฟันร่วมกับการเสริมกระดูก คอนเซนเทรตโกรทแฟกเตอร์ สภาวะปริทันต์

**Abstract** Using concentrated growth factors (CGF) in augmented-corticotomy assisted orthodontics (ACAO) has been proven to be an effective procedure for gaining labial bone thickness at middle 1/3 and apical 1/3 of root length as well as accelerated orthodontic tooth movement after surgery. This continued study aimed to evaluate the periodontal status after using CGF with ACAO in adult orthodontic patients at each treatment period. The periodontal status of 8 patients was evaluated using 5 clinical parameters: probing depth (PD), gingival margin level (CEJ-GM), clinical attachment loss (CAL), attached gingiva width (AG), and tooth stability (TS). The data were collected before surgery (T0), six months after surgery (T6), and one year after surgery (T12). For the results, the mean PD significantly decreased from T0 to T6 and T12. CEJ-GM significantly increased from T0 to T6 and T12. CAL had no significant change from T0 to T6 and T12. AG significantly increased from T0-T6 and then significantly decreased from T6-T12. TS decreased at T6, T12 when compared to the baseline (T0). For conclusions, ACAO using CGF had both positive and negative effects, this procedure can reduce PD, maintain CAL and TS within the safety limit, and increase AG after surgery, however the increased CEJ-GM might be the disadvantage of this technique.

**Keywords:** augmented-corticotomy assisted orthodontics, concentrated growth factor, periodontal status

## Introduction

The number of adult patients in orthodontics has increased.<sup>(1-3)</sup> Treatment in adults is different from adolescents and there are many limitations in adult patients, such as the long treatment time due to the harder density of the bone, thin labial plate and gingival biotype, and poor periodontal status.

The surgical assisted procedures, such as corticotomy<sup>(4,5)</sup>, cause insults to the bone that trigger

higher osteoclastic activity leading to a decrease in the alveolar bone density and reduction in the resistance of the alveolar bone<sup>(4-6)</sup> that makes the tooth move faster. The loss of alveolar bone can resolve from remineralization as the regional acceleratory phenomenon occurs, but the remineralization process is incomplete in adults and makes the periodontal support of the involved teeth become worse.<sup>(6-8)</sup> In addition, facial tooth movement in orthodontic ex-

pansion mechanics may cause the gingival recession defect and dehiscence when the gingival biotype is thin scalloped and accompanied with inflammation due to plaque retention.<sup>(9,10)</sup> Therefore, this is a disadvantage of this procedure in adult patients.

Recently in 2020, Kumchai et al.<sup>(11)</sup> studied the use of the augmented-corticotomy assisted orthodontic (ACAO) procedure combined with concentrated growth factors (CGF) in 8 orthodontic patients. The researchers evaluated labial bone thickness (LBT) via cone-beam computerized tomography (CBCT) immediately after surgery, at 6 months after surgery, and 1 year after surgery. The results of this study showed the effectiveness of gaining bone at middle 1/3 and apical 1/3 of root length, and demonstrated stability at the one-year stage. Moreover, the study of tooth movement from Visetsiri et al<sup>(12)</sup> showed the gradual decrease of Little's irregularity index after the first week, and at 1 month, 3 months, 6 months, and 1 year after surgery, respectively. Seven out of 8 patients were satisfied with the results of the treatment and no severe complication from the surgical procedure was reported. Therefore, ACAO combined with CGF is an effective procedure for accelerated orthodontic tooth movement and increases the alveolar bone of the involved teeth in adult orthodontic patients.

Moreover, from the tissue engineering concept, this manipulation usually involves 3 elements. When using CGF in ACAO, growth factors in CGF membranes as the signaling molecules, sticky bone as the scaffold, and stem cells from bleeding around the decorticated areas, periodontal regeneration may occur and can maintain or even improve periodontal status in adult orthodontic patients with this technique.

Thus, this study was continued from the work of Kumchai et al<sup>(11)</sup> and Visetsiri et al<sup>(12)</sup> and aimed to evaluate clinical periodontal status in ACAO using CGF

at each treatment period.

## Materials and methods

Ten patients with 7 maxillary arches and 9 mandibular arches who followed the inclusion criteria were selected from the Orthodontic Clinic, Bangkokthonburi University. The sample size was determined using G\*Power software, version 3.1.9.7 with values of mean and standard deviation from the literature for calculating the effect size (d). Effect size was estimated to be 1.7, alpha error probability of 0.05 and power of the study 0.97, with five degrees of freedom. A minimum sample size of 6 samples per arch was estimated. Still a higher sample was taken. Approval for research activities was received from the human ethics committee. Written informed consent was obtained from all patients before initiation of the study.

The inclusion criteria composed of 1) adult orthodontic patients (more than 30 years), 2) mild to severe anterior tooth crowding, 3) moderate periodontal involvement, 4) thin gingival biotype and thin labial plates, and 5) patients who needed short treatment time. The exclusion criteria composed of 1) smoking patient, 2) long term use of nonsteroidal anti-inflammatory drugs (NSAIDs) and corticosteroids during the study 3) use of bisphosphonate drugs before and during the study, 4) compromised patients with the surgical procedure, 5) pregnancy, 6) loss follow-up, and 7) uncontrolled periodontal diseases.

## Initial treatment

The adult orthodontic patients were referred to the periodontist for evaluating their periodontal status by full mouth periodontal charting, then initial therapy was started with scaling and root planing. Two weeks after initial therapy, the patient was re-evaluated to assess periodontal healing with the second full

mouth periodontal charting by the same periodontist. The anterior teeth that followed the inclusion criteria were selected for this study. The other areas that needed the periodontal surgery by open flap debridement in the corrective phase of periodontal treatment were treated by the same periodontist. After periodontal surgery, the patients started maintenance phase of periodontal treatment until excellent hygiene and disease resolved before started orthodontic treatment.

After re-evaluating the periodontal healing, patients received bonding with 0.018 × 0.025-inch slot self-ligated brackets (Tomy International Inc., Tokyo, Japan) and loading force with aligning archwires: 0.016-inch (Sentalloy<sup>®</sup>, Tomy International Inc.), 1 month before surgery.

### Preparation of CGF and sticky bone

Following the protocol of Sohn et al in 2016<sup>(13)</sup>, at the surgical visit, 40-60 cc of the patient's venous blood from the patient's forearm was prepared and divided into 2 groups: non-coated tubes, and coated tubes without anticoagulants. The tubes were centrifuged at 2400-2700 rpm by specific machine (Medifuge, Silfradent srl, Sofia, Italy). After 2 minutes, the centrifuge was stopped and the non-coated tubes were taken out of the centrifuge first. At this time, the non-coated tubes showed 2 different layers. The upper autologous fibrin glue (AFG) layer was taken and mixed with xenograft bone material (Bio-Oss, Switzerland), then the mixture was allowed to stand for 5-10 minutes for polymerization to get sticky bone. After taking the non-coated tubes out of the centrifuge, the vacant slot was filled with water test tubes for weight balance and the centrifuge was continued to get the CGF. After the centrifugation was completed, the coated tubes showed three different layers. The middle layer was

a fibrin buffy coat layer, which was taken and compressed with a metal cover in the metal storage box to convert to CGF membrane.

### Surgical process

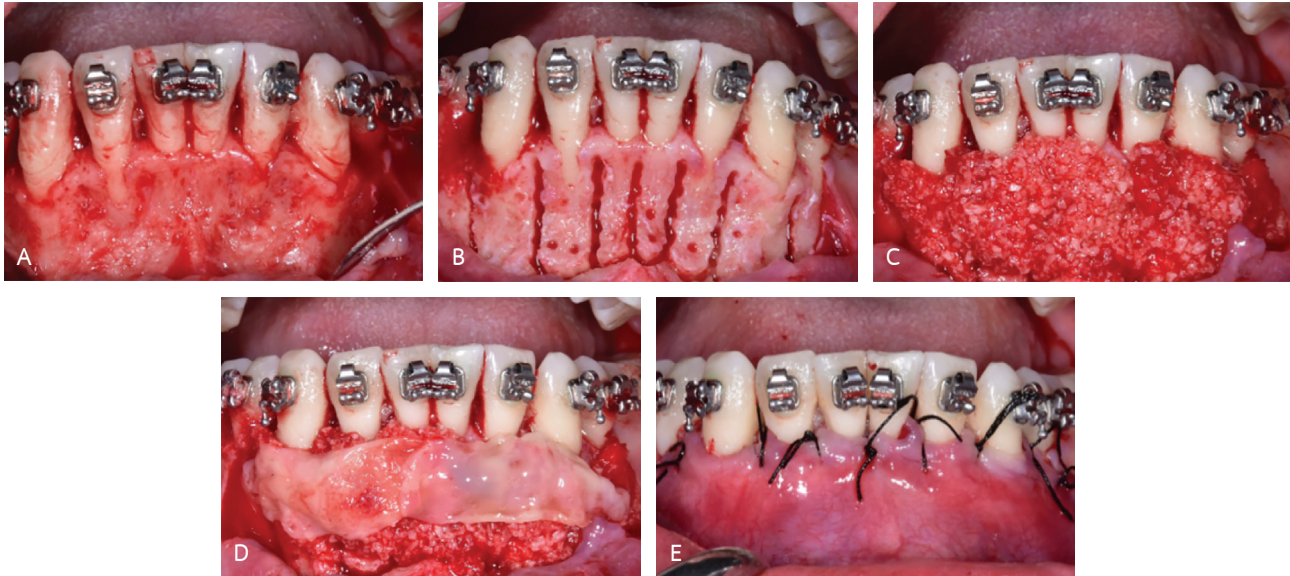
The ACAO was performed in labial side of the anterior teeth (only upper, only lower, and in both arches) depending on the indication of each area.

The flap design consisted of a full-thickness mucoperiosteal flap in the most coronal aspect and a split-thickness dissection in the apical portions with extended mesial and distal sides of the flap. After flap opening, cutting of vertical osteotomies using 010 round and fissure diamond burs (Meisinger, Germany) between the roots was initiated at 2-3 mm below the bony crest to a point 2 mm beyond the apices of the roots and then connecting each vertical line with a horizontal line. After that, perforations were made to the alveolar bone, which was then covered with sticky bone and CGF membrane. Primary closure was carried out with non-resorbable sutures. The sutures were removed after 2 weeks. (Fig. 1) Antibiotics and pain-control medications, except the nonsteroidal anti-inflammatory agents, were prescribed after surgery.

### After surgery evaluation

After the surgery, an immediate loading force on 0.016-inch wire (Sentalloy<sup>®</sup>, Tomy International Inc.) was activated every month.

Patients were recalled every 3 months for periodontal maintenance by the same periodontist. The periodontal status of each, involved the teeth of ten patients, was evaluated by five clinical parameters. The periodontal probe was used for clinical measurements: probing depth (PD), gingival margin level (CEJ-GM), clinical attachment loss (CAL), and attached



**รูปที่ 1** รายละเอียดการผ่าตัด

A: การเปิดแผ่นเหงือกชนิดเยื่อเมือก-เยื่อหุ้มกระดูก, B และ C: การใส่กระดูกปลูกถ่ายวีวีริชพันธุ์ (Bio-Oss; Geistlich AG, Wolhusen, Switzerland) ในรูปแบบกระดูกเหนียวภายหลังการกรอกระดูกที่ด้านริมฝีปากรอบ ๆ รากฟันหน้า, D: การปิดทับกระดูกที่ปลูกถ่ายด้วยแผ่นคอนเซนเทรตเต็ดโกรทแฟกเตอร์ และ E: การเย็บปิดแผล

**Fig. 1** The detailed procedure.

A: reflection of a full-thickness mucoperiosteal flap, B and C: placement of the xenograft bone material (Bio-Oss; Geistlich AG, Wolhusen, Switzerland) in sticky bone form after corticotomies into the labial bone around the anterior teeth, D: coverage with concentrated growth factor membrane over the bone grafting area, and E: suturing.

gingiva width (AG). Tooth stability (TS) was measured by tooth-mobility-measuring device (AnyCheck, Neobio-tech, Seoul, Korea of each involved tooth).

- Probing depth was measured from the gingival margin (GM) to the bottom of the sulcus.

- Gingival margin level was measured from the cemento-enamel junction (CEJ) to the gingival margin.

- Clinical attachment loss was measured from the cemento-enamel junction to the bottom of the sulcus of each involved tooth.

(PD, CEJ-GM, CAL were measured at mesiobuccal, midbuccal, and distobuccal aspects of each involved teeth)

- Attached gingiva width is measured by subtracting the depth of the sulcus or pocket from the distance between the crest of the gingival margin and the mucogingival junction.

(AG was measured at the most apical point of gingival margin of each involved teeth)

The data were collected before surgery (T0), 6 months after surgery (T6), and 1 year after surgery (T12). Tooth stability of the involved teeth was measured on every visits of orthodontic activation by two general dentists (T0, T1, T2,..., T12)

The measurements of all clinical parameters were carried out by two general dentists with the instruction by the periodontist. Before the experiments, the interindividual and intraindividual variabilities were tested to determine the reproducibility of measurement. Using twenty volunteers, all measurements were conducted two times by two general dentists to obtain four readings for each measurements. By mean of intraclass correlation coefficient, there was no evidence of a large random error between the readings

ตารางที่ 1 ค่าเฉลี่ยของพารามิเตอร์ทางคลินิก (ความลึกของร่องปริทันต์ ระยะรอยต่อเคลือบฟันและเคลือบรากฟันถึงขอบเหงือก การสูญเสียระดับยึดทางคลินิก ความกว้างของเหงือกยึด) ที่ระยะเวลาที่ 0 ที่ 6 และที่ 12 และการเปรียบเทียบความแตกต่างระหว่าง ที่ 0 ที่ 6 และที่ 12 ในขากรรไกรบน

**Table 1** The mean of clinical parameters (PD, CEJ-GM, CAL, AG) in T0, T6 and T12 and comparing the values between T0, T6 and T12 in the maxillary arch.

Maxilla	PD	CEJ-GM	CAL	AG
T0	2.51 ± 0.70	0.94 ± 1.29	3.57 ± 1.50	2.57 ± 0.56
T6	2.30 ± 0.53	1.25 ± 1.30	3.56 ± 1.31	3.23 ± 0.49
T12	2.18 ± 0.52	1.35 ± 1.22	3.53 ± 1.19	2.86 ± 0.55
T0-T6	-0.21 ± 0.05*	0.31 ± 0.07*	-0.01 ± 0.09	0.66 ± 0.09*
T6-T12	-0.11 ± 0.04*	0.11 ± 0.04*	-0.03 ± 0.05	-0.37 ± 0.08*
T0-T12	-0.32 ± 0.05*	0.41 ± 0.07*	-0.04 ± 0.10	0.29 ± 0.10*

\*statistically significant

with the reliability coefficient ranging from 0.822 to 0.990.

### Statistical analysis

With the SAS 8.02 software package (SAS Institute, Cary, NC), the descriptive statistical analysis and one-way analysis of variance (ANOVA) ( $p < 0.05$ ) was performed to compare the mean of PD, CEJ-GM, CAL, AG, and TS at T0, T6, and T12 time points.

### Results

Ten patients who followed the inclusion criteria were selected from the Orthodontic Clinic, Bangkokthonburi University. However, only 8 patients (6 females and 2 males, mean age  $46.13 \pm 6.96$  years) remained in this study because 1 patient becoming pregnant and another missing the follow-up during treatment. All patients were diagnosed as moderate chronic periodontitis. ACO was performed in anterior teeth (1 patient only upper, 2 patients only lower, and 5 patients in both arches).

The mean PD had significantly decreased from T0 ( $2.51 \pm 0.70$  mm in the upper and  $2.52 \pm 0.56$  mm in the lower) to T6 ( $2.30 \pm 0.54$  mm in the upper and

$2.25 \pm 0.55$  mm in the lower), and T12 ( $2.18 \pm 0.52$  mm in the upper and  $2.14 \pm 0.45$  mm in the lower), respectively. The CEJ-GM had significantly increased from T0 ( $0.94 \pm 1.29$  mm in the upper and  $0.48 \pm 0.97$  mm in the lower) to T6 ( $1.25 \pm 1.30$  mm in the upper and  $0.78 \pm 0.98$  mm in the lower), and T12 ( $1.35 \pm 1.22$  mm in the upper and  $1.06 \pm 0.92$  in the lower), respectively.

The CAL had not significantly changed. The T0 CALs were  $3.57 \pm 1.50$  mm in the upper and  $3.06 \pm 1.29$  mm in the lower, whereas the T6 CALs were  $3.56 \pm 1.31$  mm in the upper and  $3.06 \pm 1.15$  mm in the lower, and the T12 CALs were  $3.53 \pm 1.19$  mm in the upper and  $3.04 \pm 1.09$  mm in the lower.

The AG had significantly increased from T0 ( $2.57 \pm 0.56$  mm in the upper and  $2.36 \pm 0.73$  mm in the lower) to T6 ( $3.23 \pm 0.49$  mm in the upper and  $2.95 \pm 0.73$  mm in the lower) and then significantly decreased from T6 ( $3.23 \pm 0.49$  mm in the upper and  $2.95 \pm 0.73$  mm in the lower) to T12 ( $2.86 \pm 0.55$  mm in the upper and  $2.67 \pm 0.61$  mm in the lower) (Table 1 and 2).

In the maxillary arch, TS had significantly decreased from T0-T1 (23.3% in incisors, 19.9% in canines) and then had not significantly increased from T1-T6. From T6-T12, TS had not significantly decreased (4.0% in

**ตารางที่ 2** ค่าเฉลี่ยของพารามิเตอร์ทางคลินิก (ความลึกของร่องปริทันต์ ระยะรอยต่อเคลือบฟันและเคลือบรากฟันถึงขอบเหงือก การสูญเสียระดับยึดทางคลินิก ความกว้างของเหงือกยึด) ที่ระยะเวลาที่ 0 ที่ 6 และที่ 12 และการเปรียบเทียบความแตกต่างระหว่าง ที่ 0 ที่ 6 และที่ 12 ในขากรรไกรล่าง

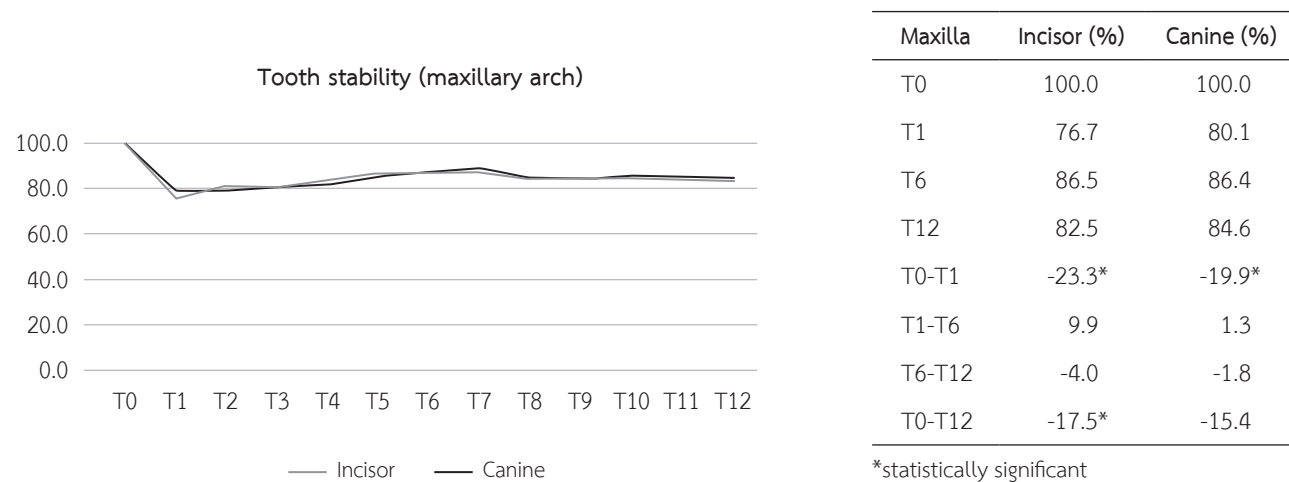
**Table 2** The mean of clinical parameters (PD, CEJ-GM, CAL, AG) in T0, T6 and T12 and comparing the values between T0, T6 and T12 in the mandibular arch.

Mandible	PD	CEJ-GM	CAL	AG
T0	2.52 ± 0.56	0.48 ± 0.97	3.06 ± 1.29	2.36 ± 0.73
T6	2.25 ± 0.55	0.78 ± 0.98	3.06 ± 1.15	2.95 ± 0.73
T12	2.14 ± 0.45	1.06 ± 0.92	3.04 ± 1.09	2.67 ± 0.61
T0-T6	-0.27 ± 0.05*	0.30 ± 0.06*	-0.00 ± 0.07	0.60 ± 0.10*
T6-T12	-0.12 ± 0.04*	0.28 ± 0.04*	-0.02 ± 0.06	-0.29 ± 0.09*
T0-T12	-0.39 ± 0.05*	0.58 ± 0.06*	-0.02 ± 0.07	0.31 ± 0.08*

\*statistically significant

**รูปที่ 2** ร้อยละของความแน่นของฟัน (เทียบกับค่าเริ่มต้น) ที่ระยะเวลาต่าง ๆ กันในขากรรไกรบน

**Fig. 2** The percentage of tooth stability (% from baseline) and time (months) in the maxillary arch.



canines, 2.8% in incisors). From T0-T12, TS had not significantly decreased in canines (15.4%) but had significantly decreased in incisors (17.5%). At T12, TS value decreased to 82.5% in incisors and 84.6% in canines (Fig. 2).

In the mandibular arch, TS had significantly decreased from T0-T1 (24.4% in incisors, 19.7% in canines) and then had not significantly increased from T1-T6. From T6-T12, TS had not significantly decreased in incisors (1.3%) but had significantly increased in canines

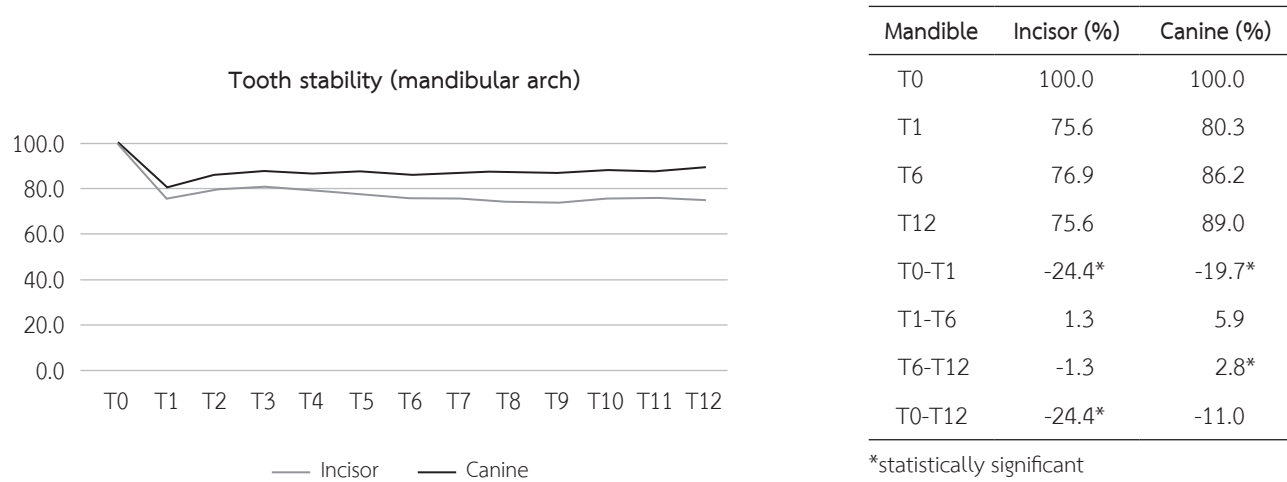
(2.8%). From T0-T12, TS had not significantly decreased in canines (11.0%) but had significantly decreased in incisors (24.4%). At T12, TS value decreased to 75.6% in incisors and 89.0% in canines (Fig. 3).

### Discussion

The patients included in this study were adult orthodontic patients with controlled periodontal disease in the initial phase of periodontal treatment or with thin gingival biotype. These patients needed

รูปที่ 3 ร้อยละของความแน่นของฟัน (เทียบกับค่าเริ่มต้น) ที่ระยะเวลาต่างๆ กันในขากรรไกรล่าง

Fig. 3 The percentage of tooth stability (% from baseline) and time (months) in the mandibular arch.



periodontal surgery in the corrective phase of periodontal treatment to avoid bone dehiscence due to orthodontic tooth movement. The surgery was performed on only the upper and lower anterior teeth because these areas usually have more crowding and thin labial bone. Orthodontic facial tooth, especially in these areas, movement may cause the gingival recession defect and dehiscence.<sup>(9,10)</sup>

In our study, we used the technique called ACAO with CGF for enhancing the periodontal healing after surgery. This was the continuation of the work from Kumchai et al<sup>(11)</sup> and Visetsiri et al<sup>(12)</sup> who used the same surgical technique.

Kumchai et al.<sup>(11)</sup> evaluated labial bone thickness via CBCT after surgical assisted orthodontic procedures by using ACAO with CGF in adult orthodontic patients. The result of this study showed the effectiveness of gaining bone at middle 1/3 and apical 1/3 of root length and demonstrated stability at 1 year postoperative. Meanwhile, Visetsiri et al<sup>(12)</sup> studied the rate of tooth movement, with the results showing a gradual decrease in Little's irregularity index after the first week, and at 1 month, 3 months, 6 months, and 1 year postoperative, respectively. Seven out of 8

patients were satisfied with the results of the treatment, and no severe complication was reported from the surgical procedures. Therefore, this study aimed to evaluate another aspect via periodontal status after surgery.

Several methods are used to determine periodontal status after surgery but the types of periodontal healing (regeneration or repair) can be defined only thorough histologic analysis. However, this approach cannot be used in human studies because of the ethical issues. Surgical re-entry is a useful method to assess the results of the treatment but it requires unnecessary second surgery. With the radiographic method, this approach needs careful repositioning of the film and tube. Many studies showed that the radiographic method is less reliable than a clinical probing approach.<sup>(14,15)</sup> Therefore in our study, we used the simple clinical method that used a periodontal probe to determine the clinical periodontal status, including PD, CEJ-GM, and CAL.

Many studies reported a similar technique (periodontally accelerated osteogenic orthodontics, PAOO) to our study and found positive results from this technique. The reports founded that alveolar



corticotomy with bone augmentation provided a significantly increasing alveolar width to support the teeth and overlying structures without any complications.<sup>(7,8,16-18)</sup> However, from our literature review, the change in clinical periodontal status had not been reported systematically. Therefore, our study is the first study that reported the change of periodontal status from this technique.

Reducing the PD is an important consideration after periodontal treatment. Presenting a deep pocket after treatment represents a greater risk of disease progression while the absence of a deep pocket is an excellent predictor of a stable periodontium<sup>(19)</sup> and enables cleaning by the patients. In the results of our study, for both maxilla and mandibular arches, the PD had significantly decreased from T0, to T6, and T12, respectively. CEJ-GM had significantly increased from T0, to T6, and T12, respectively, whereas the CAL had no significant change from T0, to T6, and T12. This finding may be due to the healing of the pocket formation from an active pocket to a healthy sulcus with no gain of attachment.<sup>(20)</sup> CEJ-GM increased because the tooth wall of the pocket was exposed. This is not because of gingival recession but from uncovering previous recession caused by periodontal disease. Because the inflammation of gingiva makes gingival enlargement to cover the cervical region of the teeth, the repair process decreases the gingival volume.<sup>(21)</sup> This may be another reason that can account for increased CEJ-GM.

The most important parameter to assess periodontal reattachment is the CAL. From the tissue engineering concept, this manipulation usually involves one or more of the three elements: signaling molecules, scaffold, and stem cells.<sup>(20)</sup> In our study, the elements are 1) CGF membrane as signaling molecules, 2) sticky bone as scaffold, and 3) the cells from bleeding

around the decorticated areas of bone as stem cells. Therefore, periodontal regeneration may occur, so maintenance or even improvement of periodontal reattachment with this technique was expected. Our results showed that CAL had no significant change from T0, to T6, and T12, respectively. According to our results, the periodontal reattachment did not occur as expected. One of the reasons is the loss of sticky bone at the coronal level that was reported by Kumchai et al.<sup>(11)</sup> Sticky bone plays a role as scaffold with osteoconductive potential that favors outside cells to penetrate the grafts to form new bone. Therefore, the loss of sticky bone ensures that periodontal regeneration cannot occur. Furthermore, periodontal defects may be difficult sites for transplantation compared to osseous cavities that are surrounded by bony walls. The contamination and exfoliation of the graft can easily occur from saliva and bacteria that penetrate along the root surface, whereas the epithelial cells can proliferate into the defect. Therefore, the principles to augment the bone into closed osseous cavities, such as periodontal defects, are not fully applicable.<sup>(22)</sup>

The goal of mucogingival surgery is the widening of the attached gingiva around teeth and implants. There were some reports that the wide attached gingiva is more protective against the accumulation of biofilm than a narrow one. From our study, the width of the attached gingiva significantly increased from T0 to T6 and then significantly decreased from T6 to T12. However, from T0-T12, the width of the attached gingiva significantly increased. The results are consistent with the study of Wilcko et al in 2015 who showed that labial keratinized tissue height increased significantly after orthodontic treatment was combined with alveolar corticotomy and bone augmentation.<sup>(23)</sup>

Tooth mobility has been investigated in relation

to the degree of periodontal support in patients with certain periodontal disease. It plays an important role to the understanding of the relationships between orthodontic biomechanics and the underlying biological processes. The degree of tooth mobility is influenced by many variables, such as the mechanical properties of the PDL and alveolar bone, thickness of the PDL space, and anatomy of the periodontium.<sup>(24)</sup> Recently, the tooth-mobility-measuring device named AnyCheck (Neobiotech, Seoul, Korea) has been developed to determine tooth and implant stability and measure the degree of osseointegration through a tapping motion. The test results are displayed in the range of 1-99, in which the numbers closely relate to the implant stability quotient (ISQ) values. A higher value refers to more stability, less mobility. Therefore, in this study we used AnyCheck to measure the TS and set the tooth stability at T0 (baseline, before surgery) to 100% and follow the drop of the percent of the tooth stability value every month. The result showed the value decreased from baseline T0 (100%) to the peak drop at T1, and then gradually increased from T1-T6. Wilcko et al<sup>(25)</sup> suggested that regional acceleratory phenomenon (RAP) in humans begins within a few days of surgery, typically peaks at 1 to 2 months, and may take from 6 to more than 24 months to subside. Therefore, we may be interpreted from the peak drop of tooth stability value in this study that RAP peak occurred at 1 month after surgery (T1) and then gradually subsided. Although from T0-T12,

there was still a decrease of tooth stability, but it was in the range of first degree mobility that we could control and was within safety limits. The teeth are still in the orthodontic process where the orthodontic force can increase the mobility of the teeth. After orthodontic treatment, the reorganization of PDL occurs over 3-4 months and the collagenous fiber networks within the gingiva normally reorganize within 4-6 months.<sup>(26)</sup> Thus, we recommend to follow the stability of the teeth until 6 months after debonding, when the tooth stability may be increased compared to the baseline (T0) and add more samples to reduce the influence of the confounding factors from the difference of orthodontic mechanics, interference from active orthodontic tooth movement and so on to see how underlying biological processes occur.

In conclusions, for positive effects, ACAO using CGF can reduce PD, maintain CAL and TS within safety limits, and increase AG after surgery. However, for negative effects, this procedure increases CEJ-GM.

For the further study, we recommend to add the control group and increase more samples for comparing to the normal case with only orthodontic treatment (without ACAO combined with CGF) for reducing the confounding factors from changing the position of the tooth which can affect the periodontal status. Maintaining the scaffold in coronal part of the root is still challenging. Therefore, this is the interesting topic that we recommend to continue study in the future.

### เอกสารอ้างอิง

1. Bagga DK. Adult orthodontics versus adolescent orthodontics: an overview. *J Oral Health Comm Dent* 2010;4:42-7.
2. Keim RG, Gottlieb EL, Nelson AH, Vogels D III. Orthodontic practice study. Part 1: trends. *J Clin Orthod* 2005;39:641.
3. Tarraf NE. The adult orthodontic patient: more options than ever before! *Dentistry* 2015;5:1.
4. Cano J, Campo J, Bonilla E, Colmenero C. Corticotomy-assisted orthodontics. *J Clin Exp Dent* 2012;4:e54.
5. Hoogveen EJ, Jansma J, Ren Y. Surgically facilitated or-

- thodontic treatment: a systematic review. *Am J Orthod Dentofacial Orthop* 2014;145:551-64.
6. Liou EJ. The development of submucosal injection of platelet rich plasma for accelerating orthodontic tooth movement and preserving pressure side alveolar bone. *APOS Trends Orthod* 2016;6:5.
  7. Wilcko MT, Wilcko WM, Pulver JJ, Bissada NF, Bouquot JE. Accelerated osteogenic orthodontics technique: a 1-stage surgically facilitated rapid orthodontic technique with alveolar augmentation. *J Oral Maxillofac Surg* 2009;67: 2149-59.
  8. Wilcko WM, Wilcko MT, Bouquot J, Ferguson DJ. Rapid orthodontics with alveolar reshaping: two case reports of decrowding. *Int J Periodontics Restorative Dent* 2001;21: 9-20.
  9. Ackerman JL, Proffit WR. Soft tissue limitations in orthodontics: treatment planning guidelines. *Angle Orthodontist* 1997;67:327-36.
  10. Dorfman HS. Mucogingival changes resulting from mandibular incisor tooth movement. *Am J Orthod Dentofacial Orthop* 1978;74:286-97.
  11. Kumchai H, Suzuki B, Suzuki EY, Kumchai T. Change of labial thickness in augmented corticotomy assisted orthodontics combined with concentrated growth factor (CGF): a cone-beam computed tomography study. *Thai J Oral Maxillofac Surg* 2020;34:35-43.
  12. Visetsiri S, Suzuki EY, Suzuki B, Kumchai T. Effectiveness of augmented corticotomy assisted orthodontics, using concentrated growth factor. Proceedings of the 8th National and 4th International Bangkokthonburi University Meeting, Bangkok, Apr 26, 2020.
  13. Sohn DS, Huang B, Kim J, Park WE, Park CC. Utilization of autologous concentrated growth factors (CGF) enriched bone graft matrix (sticky bone) and CGF-enriched fibrin membrane in implant dentistry. *J Implant Adv Clin Dent* 2015;7:11-29.
  14. Theilade J. An evaluation of the reliability of radiographs in the measurement of bone loss in periodontal disease. *U Toronto Undergrad Dent J* 1965;2:19.
  15. Lang NP, Hill RW. Radiographs in periodontics. *J Clin Periodontol* 1977;4:16-28.
  16. Wang B, Shen G, Guo Q, Fang B, Yu H. Long-term effects of augmented corticotomy-assisted orthodontics in patients with mandibular anterior alveolar defect. *J Craniofac Surg* 2019;30:e737-40.
  17. Wang B, Shen G, Fang B, Yu H, Wu Y, Sun L. Augmented corticotomy-assisted surgical orthodontics decompen-sates lower incisors in class III malocclusion patients. *J Oral Maxillofac Surg* 2014;72:596-602.
  18. Bhat SG, Singh V, Bhat MK. PAOO technique for the bi-maxillary protrusion: perio-ortho interrelationship. *J Indian Soc Periodontol* 2012;16:584.
  19. Greenstein G. Contemporary interpretation of probing depth assessments: diagnostic and therapeutic implications: a literature review. *J Periodontol* 1997;68:1194-205.
  20. Newman MG, Takei H, Klokkevold PR, Carranza FA. Carranza's clinical periodontology. 11th ed. Philadelphia: Elsevier Health Sciences; 2011. p. 586-7.
  21. Jati AS, Furquim LZ, Consolaro A. Gingival recession: its causes and types, and the importance of orthodontic treatment. *Dent Press J Orthod* 2016;21:18-29.
  22. Ellegaard B. Bone grafts in periodontal attachment procedures. *J Clin Periodontol* 1976;3:1-54.
  23. Wilcko MT, Ferguson DJ, Makki L, Wilcko WM. Keratinized gingiva height increases after alveolar corticotomy and augmentation bone grafting. *J Periodontol* 2015;86:1107-15.
  24. Tanne K, Inoue Y, Sakuda M. Biomechanical behavior of the periodontium before and after orthodontic tooth movement. *Angle Orthodontist* 1995;65:123-8.
  25. Wilcko WM, Wilcko T, Bouquot JE, Ferguson DJ. Rapid orthodontics with alveolar reshaping: two case reports of decrowding. *Int J Periodontics Restorative Dent* 2001; 21:9-19.
  26. Proffit WR, Fields Jr HW, Sarver DM. Contemporary orthodontics. Philadelphia: Elsevier Health Sciences; 2006. p. 606-7.