

การวิเคราะห์สามมิติของการเคลื่อนฟันกรามบนไปด้านไกลกลางแบบไม่ สมมาตรโดยใช้เครื่องมือไอแพนด้า

Three-dimensional analysis of asymmetrical maxillary molar distalization using the indirect Palatal Miniscrew Anchorage and Distalization Appliance (iPanda)

กมลทิพย์ สุจริตวานิช¹, บุญสิวา ซูซูกิ² และเอ็ดวาร์โด ยูโก้ ซูซูกิ³

Kamontip Sujaritwanid¹, Boonsiva Suzuki² and Eduardo Yugo Suzuki³

^{1,2,3} สาขาวิชาทันตกรรมจัดฟัน คณะทันตแพทยศาสตร์ มหาวิทยาลัยกรุงเทพธนบุรี โทรศัพท์ 028006800

^{1,2,3} Department of Orthodontics, Faculty of Dentistry, Bangkokthonburi University, Tel. 028006800

¹e-mail: kamontip.su@hotmail.com

บทคัดย่อ

วัตถุประสงค์ของการศึกษาทางคลินิกนี้เพื่อที่จะประเมินการเปลี่ยนแปลงของฟัน และผลข้างเคียง จากการถอยฟันกรามไปด้านไกลกลาง โดยใช้วิธีการสแกนช่องปากสามมิติ ผู้ป่วย 41 คน (อายุเฉลี่ย 25.2 ± 2.3 ปี) สบฟันผิดปกติประเภทที่ 2 ผู้ป่วยทุกรายได้รับการรักษาโดยใช้เครื่องมือไอแพนด้าเพื่อเคลื่อนฟันไปด้านไกลกลางด้านเดียวและสองด้าน โมเดลสามมิติถูกสร้างขึ้นก่อนและหลังการถอยฟันไปด้านไกลกลาง โมเดลทั้งสองถูกนำมาซ้อนทับกันโดยใช้พื้นที่บริเวณเพดานปากที่เหมือนกันซ้อนทับกัน ซึ่งเป็นบริเวณเพดานส่วนลอน เพื่อเป็นจุดอ้างอิง การเคลื่อนที่ของฟันกรามถูกวัดบนโมเดลที่ซ้อนทับกันก่อนและหลังการเคลื่อนฟันไปด้านไกลกลาง ผลการวิจัยพบการเปลี่ยนแปลงการสบฟันเป็นการสบฟันประเภทที่ 1 ฟันกรามเคลื่อน 0.6 มิลลิเมตรต่อเดือน ในแนวระนาบหน้าหลัง ฟันกรามซี่ที่ 1 แสดงการเคลื่อนที่เส้นตรง 3.12 มิลลิเมตร ± 0.91 มิลลิเมตร และองศาฟันเฉลี่ยเปลี่ยนแปลง 4.29 องศา ± 2.87 องศา ในแนวตั้งฟันกรามบนซี่ที่ 1 แสดงการเคลื่อนที่ลงไปทางปลากราก เฉลี่ย 0.83 มิลลิเมตร ± 0.81 มิลลิเมตร ในแนวตัดขวางพบฟันกรามบนซี่ที่ 1 หมุน 2.33 องศา ± 2.11 องศา การรักษาการสบฟันผิดปกติประเภทที่ 2 สามารถทำได้โดยไม่ถอนฟัน โดยใช้เครื่องมือไอแพนด้าเพื่อเคลื่อนฟันไปด้านไกลกลาง องศาฟันถูกควบคุมได้และพบผลข้างเคียงในแนวตั้งและแนวขวางเล็กน้อย

คำสำคัญ: การสบฟันผิดปกติประเภทที่ 2, การเคลื่อนฟันไปด้านไกลกลาง, มินิสกรู

Abstract

The purpose of this clinical study was to evaluate the dentoalveolar changes due to maxillary molar distalization and to determine side effects using a 3-dimensional intraoral scanning method. The study group comprised 41 patients (mean age, 25.2 ± 2.3 years) with a Class II molar relationship. All patients were treated with the iPanda for unilateral and bilateral maxillary molar distalization. Three-dimensional models were obtained before and

after distalization. Digital models were superimposed using surface-to-surface matching of the palatal area which is rugae as a reference area. Molar movement was measured on the superimposed maxillary arches before and after distalization. The results showed that Class I molar relationship was obtained, with a movement rate of 0.6 mm per month. In the sagittal plane, the first molars showed a mean linear movement of 3.12 mm \pm 0.91 mm and the average molar inclination was 4.29° \pm 2.87°. In the vertical plane, the first molars showed slight intrusion, with a mean value of 0.83 mm \pm 0.81 mm. In the transverse plane, the rotation of the first molars was 2.33° \pm 2.11°. Non-extraction treatment for Class II subdivision malocclusions was achieved by iPanda for unilateral or bilateral molar distalization. Controlled angulation movement of maxillary molars was observed with slight side effects in the vertical and transverse plane.

Keywords: Class II Malocclusion, Maxillary Molar Distalization, Miniscrew

Introduction

Maxillary molar distalization is an important alternative treatment for correction of Class II malocclusions by distalizing the first molars to occlude into a Class I relationship and facilitate space for correction crowding and reducing the overjet. (Escobar et al., 2007; Kinzinger, Gülden, Yildizhan, & Diedrich, 2009)

Several tooth-borne distalizing devices have been introduced to correct class II malocclusion. (Bolla, Muratore, Carano, & Bowman, 2002) However, undesirable side effects were observed in the anchorage unit, represented by tipping and extrusion of the maxillary premolars, maxillary anterior crowding, or increased protrusion. (Fuziy, de Almeida, Janson, Angelieri, & Pinzan, 2006)

In order to avoid anchorage loss, miniscrew has become a valuable practice for numerous orthodontic treatments. This is because it provides absolute anchorage and eliminates the necessity of patient compliance. (Fudalej & Antoszewska, 2011) The miniscrews can be implanted in various areas, depending on the orthodontic mechanics. The palate area has been indicated as a safe area for placement miniscrew due to no risk of dental injury from tooth contact, sufficient bone thickness, provide primary stability, and minimal invasiveness. Especially, placement miniscrew in this area does not interfere with dental movement during distalization. (Poon et al., 2015) Recently, an innovative miniscrew-supported distalization device in the palatal area namely the “indirect Palatal Anchorage and Distalization Appliance” (iPanda) was introduced to allow controlled movement of maxillary molar teeth during distalization. Since the maxillary molars were indirectly anchored

to the midpalatal miniscrews by the iPanda, without anchorage loss occurs in adults and adolescents. (Suzuki & Suzuki, 2013, 2016) However, there is no study about the tooth movement in three dimensions using the iPanda.

Objectives

The purpose of this clinical study was to evaluate the dentoalveolar changes due to maxillary molar distalization and to determine side effects using a 3-dimensional intraoral scanning method.

Review of Literatures

Headgear has been a conventional modality for Class II malocclusion for distalization of molars. Headgear is effective only if it has been applied to patients for more than 14 hours a day with heavy force applied to the dentition. However, the main disadvantage is patient compliance, which is difficult due to social and esthetic concerns. (Egolf, BeGole, & Upshaw, 1990)

To avoid the limitations of extra-oral appliances, various types of intraoral appliances, such as Repelling Magnets, Distal Jet, Jones Jig, Sliding Jig, and Pendulum, have been developed. The main advantage of these devices is to apply continuous forces to distalize the maxillary molars and not need patient compliance. However, they provide first molar distal tipping and extrusion, as well as the mesial reaction cause anchorage loss and anterior tooth proclination. (Fuziy et al., 2006)

To eliminate undesirable side effects, skeletal anchorage systems or Temporary Anchorage Devices (TADs) such as miniscrew, miniplate have been introduced. TADs have been combined with an intraoral device to reinforce anchorage and eliminate labial flaring. (Cornelis & De Clerck, 2007; Yu et al., 2014) Numerous clinical skeletal anchorage options are available for maxillary molar distalization. The selection of each method depends upon the location of the TAD insertion, such as buccal alveolar bone (Interradicular area), infrazygomatic crest, and palatal bones. (Duran, Gorgulu, & Dindaroglu, 2016)

However, buccal interradicular sites may sometimes involve a specific surgical protocol to avoid root damage, require additional radiographic examinations, (Poggio, Incorvati, Velo, & Carano, 2006) and represent an obstacle to spontaneous retraction of premolars during the distalization of the first molar. As a result, the most appropriate insertion site is in either the paramedian or midpalatal area. (Gracco, Lombardo, Cozzani, & Siciliani, 2008; Ludwig, Glasl, Kinzinger, Walde, & Lisson, 2011)

Research Methodology

Subjects

Forty-one patients, consisting of 30 females and 11 males (mean age, 25.2 ± 2.3 years) with Class II molar dental relationship who were undergoing the use of iPanda for molar distalization as part of their orthodontic treatment plan at the Department of Orthodontics, Bangkokthonburi University were recruited. The institutional review board approved the retrospective study at Bangkokthonburi University (approval number: 1/2561). All subjects were treated with a fixed appliance, which the main archwire was 0.016 × 0.022 inches NiTi, brackets 0.018-inch slots, and the iPanda for bilateral and unilateral maxillary molar distalization. The iPanda used in this study was similar to that described by Suzuki and Suzuki. (Suzuki & Suzuki, 2013)

Orthodontic Loading Condition

Two hundred grams of force was applied to the iPanda with open coil spring. Loading duration was recorded from the beginning of activating the application until the end of the distalization phase of each patient. The iPanda was re-activated monthly.

Model and Cephalometric Measurement

The pre-distalization (T0) and post-distalization (T1) of intraoral models were imported to the OrthoAnalyzer™ analytical software (3Shape Dental Systems, Copenhagen, Denmark). Reference planes for measurement were constructed in the sagittal, transverse, and vertical planes through the palatal miniscrews at T0 for all subjects (Figure 1).

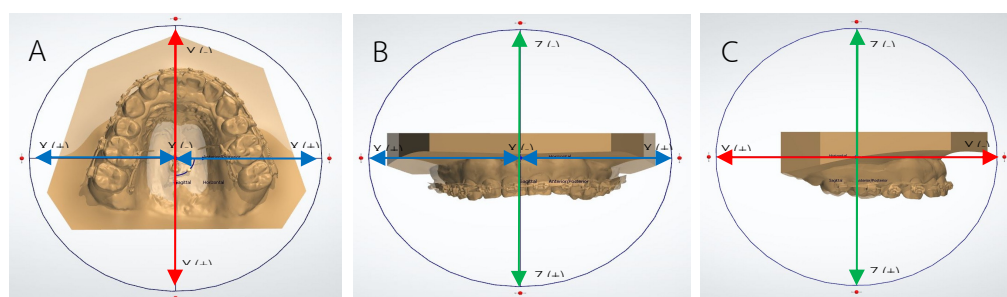


Figure 1 Reference coordinate system and directions: A, occlusal view; B, frontal view; C, sagittal view. X(+), buccal direction; X(-), palatal direction; Y(+), distal direction; Y(-), mesial direction; Z(+), extrusion; Z(-), intrusion

The pre and post distalization models were superimposed with a surface-to-surface matching method in the palatal area, which included the rugae and palatal vault as references. (Choi, Jeong, Jang, Jost-Brinkmann, & Cha, 2010; Jang et al., 2009) The linear and angular tooth changes were measured three-dimensionally on the superimposed models (Figure 2).

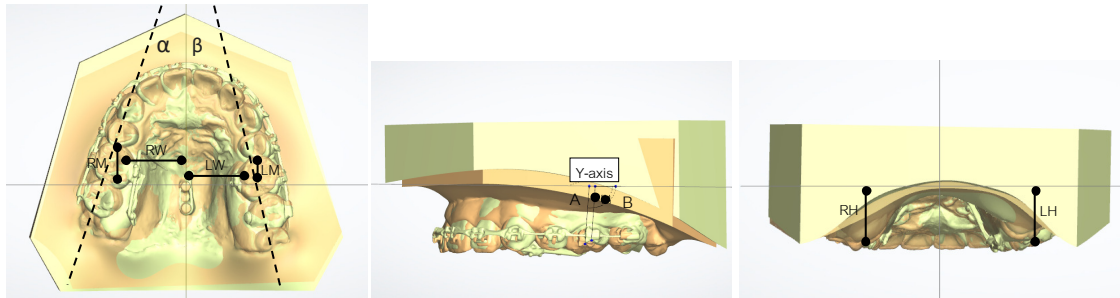


Figure 2 Measurement of the superimposed 3D digital models

The same investigator determined reference points and lines. The reference landmarks followed by Suzuki (Suzuki & Suzuki, 2013) are shown in Table 1. The distance between reference points was measured linearly to the reference line.

Table 1 The reference landmarks for clinical measurement

Landmark	
α, β	The angle between the constructed line passing through the central groove of the first molars and the X-axis. α and β were calculated to identify any rotational changes that may occur during the distalization right and left side, respectively.
RW, LW	The distance between the mesiopalatal cusp tip of the right or left of 1st maxillary molar and the Y-axis. To identify possible changes in the arch width.
RM, LM	The distance between the mesial contact point of the right or left of 1st maxillary molar and the X-axis.
RH, LH	The distance between the mesiopalatal cusp tip of the right or left of 1st maxillary molar and the Z-axis. To identify possibilities in the vertical changes.
A, B	The angle between the Facial axis (FA) of the first molars and the Y-axis. A and B were calculated to identify how many degrees of tipping may occur during the distalization right and left side, respectively.

Lateral cephalometric radiographs of the in pre and post distalization phase were superimposed at the miniscrews. The linear and angular changes of the first maxillary molar and central incisor were investigated using Smart Ceph software. The linear and angular tooth movements were measured (Figure 3).

Statistical Analysis

In the clinical studies, descriptive analyses were made using SPSS for Windows software (version 20.0; SPSS, Armonk, NY). The means, standard deviations, and minimum and maximum values of the linear and angular changes in the x, y, and z planes were calculated at the first molar.

To evaluate the reliability of the measurements, the reference landmarks were digitized twice and all samples were measured on two occasions 2 months apart by one examiner. Intraclass correlation coefficients for the linear and angular variables were used to assess intra-examiner reliability.

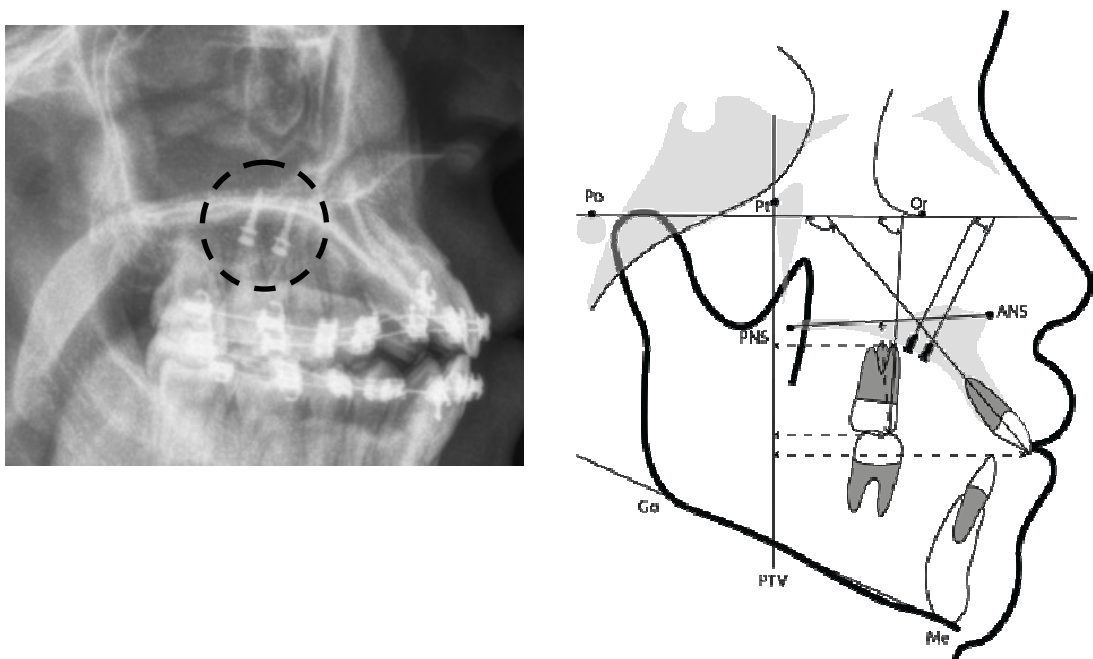


Figure 3 Cephalometric analysis: angles and distances in cephalogram measured before and after molar distalization (changes in the sagittal and vertical plane)

Research Results

Pre and post distalization were evaluated in virtual model in 3 planes when using iPanda with buccal open coil spring for distalization. In all cases, Class I molar and canine relationship was obtained in 7.4 ± 2.8 months. Maxillary second molars

were controlled distalization (Figure 4, 5). In the sagittal direction, the first molars showed a mean linear distal movement of $3.12 \text{ mm} \pm 0.91 \text{ mm}$. For angular movements, the amounts of mean distal tipping were of first molar $4.29^\circ \pm 2.87^\circ$. In the transverse direction, a slight expansion of the first molar was observed, with a mean value of $3.32 \text{ mm} \pm 0.97 \text{ mm}$ per side; rotation of the first molars were $2.33^\circ \pm 2.11^\circ$ distal-out rotation. In the vertical direction, the first molars were shown slight extrusion or intrusion depended on extension arm adjustment, with a mean value of intrusion $0.83 \text{ mm} \pm 0.81 \text{ mm}$ (Table 2). In cephalometric showed that the first molar angulation was changed in $4.16^\circ \pm 3.17^\circ$.

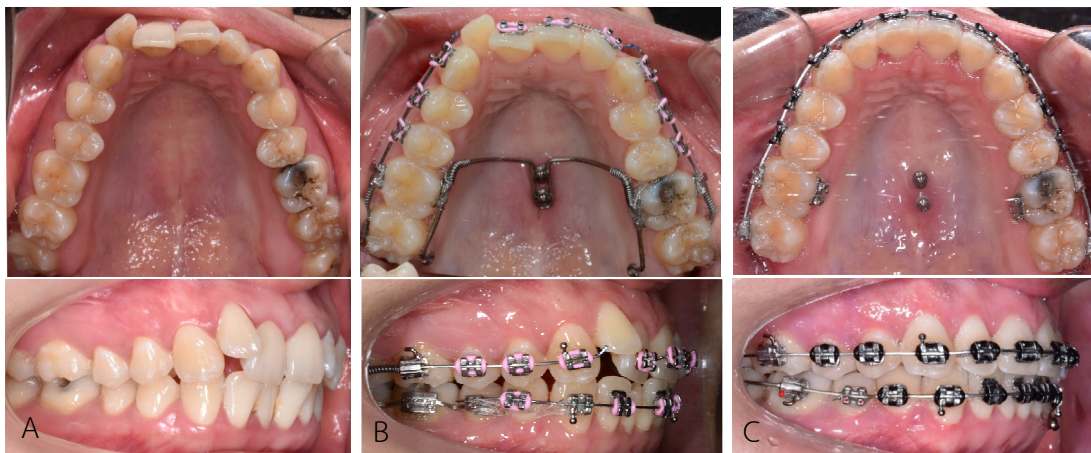


Figure 4 The clinical pictures (A) Before orthodontic treatment (B) Placement of iPanda, with bilateral closed-coil springs for molar distalization and (C) After distalization

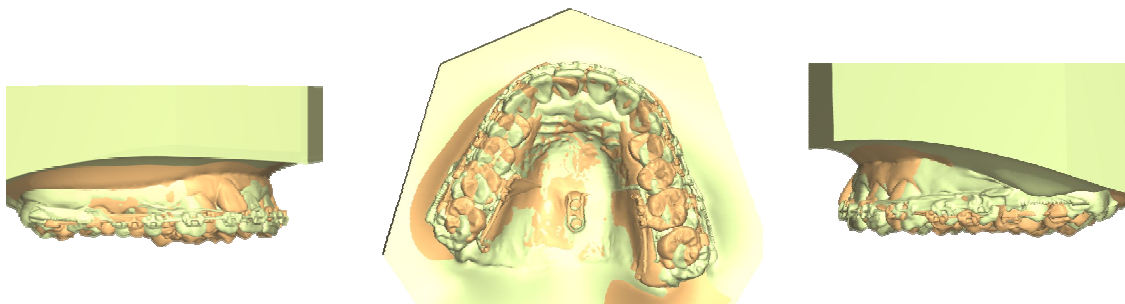


Figure 5 Superimposition of pre- and post-distalization in the visual scanned model

Table 2 The values of tooth movement in the models (n=41)

		Mean	S.D.	Max	Min
Linear (mm)	Amount of molar distalization	3.12	0.91	4.08	1.10
	Molar width	3.32	0.97	3.56	0.11
	Height	-0.83	0.81	-1.89	0.20
Angular (°)	Rotation	2.33	2.11	13.00	0.00
	Angulation - 3D model	4.29	2.87	13.00	0.10
	- Cephalogram	4.16	3.17	12.00	0.50

Discussions

Treatment of Class II malocclusion in the adolescent period by temporary skeletal anchorage devices, such as miniscrew implants, have become a valuable practice for numerous orthodontic treatments. This is because they provide absolute anchorage and eliminate the necessity of patient compliance. (Oberti, Villegas, Ealo, Palacio, & Baccetti, 2009)

This study aimed to evaluate the displacement pattern of the maxillary molar during distalization in three-dimension using the three-dimensional model and lateral cephalogram. Three-dimension reverse engineering technology has been suggested that could be an alternative to the conventional cephalometric technique for more accurate analysis of orthodontic tooth movement. (Choi et al., 2010) Many studies have reported that the maxillary dental casts can be superimposed reliably using the medial points of the third rugae and the palatal vault for constructing landmarks for pre- and post-treatment. (Hoggan & Sadowsky, 2001; Jang et al., 2009) Conversely, angulation change of the root tip position not able to measure precisely by the dental cast. Therefore, in this study, the authors used a 3D reverse engineering method and cephalometric analysis to evaluate dental changes after the distalization phase.

During seven months, the results showed an average of 3.12 mm molar distalization with distal tipping 4.29°. While the other studies showed 10.9° - 11.3° of distal tipping of the maxillary first molars. (Kinzingler et al., 2009; Kircelli, Pektas, & Kircelli, 2006) This decreased tipping in our study might be due to the design of the appliance that allows tooth sliding along the rigid palatal wire. Therefore, The first molar can be distalized with slightly distal tipping

In the transverse plane, the buccal displacement patterns in our study which is slight buccal tipping agree with Kang et al. (Kang et al., 2016), who reported that when the second molar completely erupted, buccal tipping of the first molar was increased more

than without second molar. However, many clinical studies can distalize the first and second molar simultaneously, which are performed in children (average age 13.2-14.58year).(Fuzyi et al., 2006; Mavropoulos, Karamouzou, Kiliaridis, & Papadopoulos, 2005) Moreover, the distal out rotation was detected at the first molar. This might due to the distalization force was on the palatal side and do not pass through the center of resistance which is located within the trifurcation area. (Field et al., 2009)

Yu et al. (Yu et al., 2014) stated that occlusal relations can worsen if molar extruded during treatment in open configuration cases. Therefore, the clinician should ensure intrusion or maintenance of the pre-treatment molar position during distalization. In the present study, the mean value of vertical changes showed intrusion. However, the force vector of this appliance can be modified by palatal bar adjustment for control vertical and transverse changes.

Non-extraction treatment for Class II subdivision malocclusions was achieved by iPanda for unilateral or bilateral molar distalization. Controlled angulation movement of maxillary molars was observed with slight side effects in the vertical and transverse plane.

Recommendations for Further Study

Further clinical studies are necessary to determine the biomechanical effects to generate information on biomechanical responses of teeth, PDL, and bone throughout the orthodontic treatment. The time-dependent (continuous/dynamic) finite element approach can help in exploring such changes to yield accurate mathematical simulations of the biologic processes of tooth movements over time (including the PDL and bony reactions).(Ammar, Ngan, Crout, Mucino, & Mukdadi, 2011)

References

- Ammar, H. H., Ngan, P., Crout, R. J., Mucino, V. H., & Mukdadi, O. M. (2011). Three-dimensional modeling and finite element analysis in treatment planning for orthodontic tooth movement. *Am J Orthod Dentofacial Orthop*, 139(1), e59-71. doi:10.1016/j.ajodo.2010.09.020
- Bolla, E., Muratore, F., Carano, A., & Bowman, S. J. (2002). Evaluation of maxillary molar distalization with the distal jet: a comparison with other contemporary methods. *Angle Orthod*, 72(5), 481-494. doi:10.1043/0003-3219(2002)072<0481: EOM MDW>2.0.CO;2
- Choi, D.-S., Jeong, Y.-M., Jang, I., Jost-Brinkmann, P. G., & Cha, B.-K. (2010). Accuracy and reliability of palatal superimposition of three-dimensional digital models. *Angle Orthod*, 80(4), 685-691. doi:10.2319/101309-569.1

- Cornelis, M. A., & De Clerck, H. J. (2007). Maxillary molar distalization with miniplates assessed on digital models: a prospective clinical trial. *Am J Orthod Dentofacial Orthop*, 132(3), 373-377. doi:10.1016/j.ajodo.2007.04.031
- Duran, G. S., Gorgulu, S., & Dindaroglu, F. (2016). Three-dimensional analysis of tooth movements after palatal miniscrew-supported molar distalization. *Am J Orthod Dentofacial Orthop*, 150(1), 188-197. doi:10.1016/j.ajodo.2015.12.024
- Egolf, R. J., BeGole, E. A., & Upshaw, H. S. (1990). Factors associated with orthodontic patient compliance with intraoral elastic and headgear wear. *Am J Orthod Dentofacial Orthop*, 97(4), 336-348. doi:10.1016/0889-5406(90)70106-M
- Escobar, S. A., Tellez, P. A., Moncada, C. A., Villegas, C. A., Latorre, C. M., & Oberti, G. (2007). Distalization of maxillary molars with the bone-supported pendulum: a clinical study. *Am J Orthod Dentofacial Orthop*, 131(4), 545-549. doi:10.1016/j.ajodo.2006.08.012
- Field, C., Ichim, I., Swain, M. V., Chan, E., Darendeliler, M. A., Li, W., & Li, Q. (2009). Mechanical responses to orthodontic loading: a 3-dimensional finite element multi-tooth model. *Am J Orthod Dentofacial Orthop*, 135(2), 174-181. doi:10.1016/j.ajodo.2007.03.032
- Fudalej, P., & Antoszewska, J. (2011). Are orthodontic distalizers reinforced with the temporary skeletal anchorage devices effective? *Am J Orthod Dentofacial Orthop*, 139(6), 722-729. doi:10.1016/j.ajodo.2011.01.019
- Fuziy, A., de Almeida, R. R., Janson, G., Angelieri, F., & Pinzan, A. (2006). Sagittal, vertical, and transverse changes consequent to maxillary molar distalization with the pendulum appliance. *Am J Orthod Dentofacial Orthop*, 130(4), 502-510. doi:10.1016/j.ajodo.2004.12.031
- Gracco, A., Lombardo, L., Cozzani, M., & Siciliani, G. (2008). Quantitative cone-beam computed tomography evaluation of palatal bone thickness for orthodontic miniscrew placement. *Am J Orthod Dentofacial Orthop*, 134(3), 361-369. doi:10.1016/j.ajodo.2007.01.027
- Hoggan, B. R., & Sadowsky, C. (2001). The use of palatal rugae for the assessment of anteroposterior tooth movements. *Am J Orthod Dentofacial Orthop*, 119(5), 482-488. doi:10.1067/mod.2001.113001
- Jang, I., Tanaka, M., Koga, Y., Iijima, S., Yozgatian, J. H., Cha, B. K., & Yoshida, N. (2009). A novel method for the assessment of three-dimensional tooth movement during orthodontic treatment. *Angle Orthod*, 79(3), 447-453. doi:10.2319/042308-225.1
- Kang, J.-M., Park, J. H., Bayome, M., Oh, M., Park, C. O., Kook, Y.-A., & Mo, S.-S. (2016). A three-dimensional finite element analysis of molar distalization with a palatal plate, pendulum, and headgear according to molar eruption stage. *The Korean Journal of Orthodontics*, 46(5). doi:10.4041/kjod.2016.46.5.290

- Kinzinger, G. S. M., Gülden, N., Yildizhan, F., & Diedrich, P. R. (2009). Efficiency of a skeletonized distal jet appliance supported by miniscrew anchorage for noncompliance maxillary molar distalization. *Am J Orthod Dentofacial Orthop*, *136*(4), 578-586. doi:10.1016/j.ajodo.2007.10.049
- Kircelli, B. H., Pektas, Z. O., & Kircelli, C. (2006). Maxillary molar distalization with a bone-anchored pendulum appliance. *Angle Orthod*, *76*(4), 650-659. doi:10.1043/0003-3219(2006)076[0650:Mmdwab]2.0.Co;2
- Ludwig, B., Glasl, B., Kinzinger, G. S., Walde, K. C., & Lisson, J. A. (2011). The skeletal frog appliance for maxillary molar distalization. *J Clin Orthod*, *45*(2), 77-84; quiz 91.
- Mavropoulos, A., Karamouzos, A., Kiliaridis, S., & Papadopoulos, M. A. (2005). Efficiency of noncompliance simultaneous first and second upper molar distalization: a three-dimensional tooth movement analysis. *Angle Orthod*, *75*(4), 532-539. doi:10.1043/0003-3219(2005)75[532:Eonsfa]2.0.Co;2
- Oberti, G., Villegas, C., Ealo, M., Palacio, J. C., & Baccetti, T. (2009). Maxillary molar distalization with the dual-force distalizer supported by mini-implants: a clinical study. *Am J Orthod Dentofacial Orthop*, *135*(3), 282 e281-285; discussion 282-283. doi:10.1016/j.ajodo.2008.11.018
- Poggio, P. M., Incorvati, C., Velo, S., & Carano, A. (2006). "Safe zones": a guide for miniscrew positioning in the maxillary and mandibular arch. *Angle Orthod*, *76*(2), 191-197. doi:10.1043/0003-3219(2006)076[0191:Szagfm]2.0.Co;2
- Poon, Y. C., Chang, H. P., Tseng, Y. C., Chou, S. T., Cheng, J. H., Liu, P. H., & Pan, C. Y. (2015). Palatal bone thickness and associated factors in adult miniscrew placements: A cone-beam computed tomography study. *Kaohsiung J Med Sci*, *31*(5), 265-270. doi:10.1016/j.kjms.2015.02.002
- Suzuki, E. Y., & Suzuki, B. (2013). Maxillary molar distalization with the indirect Palatal miniscrew for Anchorage and Distalization Appliance (iPANDA). *Orthodontics (Chic.)*, *14*(1), e228-241. doi:10.11607/ortho.982
- Suzuki, E. Y., & Suzuki, B. (2016). The Indirect Palatal Miniscrew Anchorage and Distalization Appliance. *J Clin Orthod*, *50*(2), 80-96.
- Yu, I. J., Kook, Y. A., Sung, S. J., Lee, K. J., Chun, Y. S., & Mo, S. S. (2014). Comparison of tooth displacement between buccal mini-implants and palatal plate anchorage for molar distalization: a finite element study. *Eur J Orthod*, *36*(4), 394-402. doi:10.1093/ejo/cjr130