



Orthodontic Extraction of Impacted Mandibular Third Molar Using the Minimally Invasive Bracket System

Somyot Limpanaputtajak

Boonsiva Suzuki

Eduardo Yugo Suzuki

Reprinted from The Journal of The Dental Association of Thailand

Volume 71 Number 1 January – March 2021

page 44-52

Orthodontic Extraction of Impacted Mandibular Third Molar Using the Minimally Invasive Bracket System

Somyot Limpanaputtajak¹, Boonsiva Suzuki¹, Eduardo Yugo Suzuki¹

¹Department of Orthodontics, Faculty of Dentistry, Bangkokthonburi University, Bangkok, Thailand

Abstract

The purpose of this study was to introduce the application of an orthodontic extraction (OE) with a reinforced dental device, called “minimally invasive bracket (MIB)”, to an upright impacted mandibular third molar (MI8) before extraction. The performance of the MIB for OE of an MI8 was investigated. Twenty-four MI8s, planned for OE, were divided into two groups. In the MIB group (n= 12), the MI8s were uprighted with anchorage reinforcement of posterior teeth provided by the MIB. In the control group (n= 12), the MI8s were uprighted without any anchorage reinforcement. All MI8s were removed by simple extraction after the uprighting process. Lateral cephalograms and panoramic radiographs were taken at the beginning (T0) and by the end (T1) of the uprighting process. Using T0 and T1 radiographs, altered movement and angulation of the MI8 (moving unit) and adjacent second molars (anchorage unit) were monitored and compared between the two groups. For the moving unit, the amount and rate of MI8 distalization between the MIB (1.8 ± 1.0 mm, 0.9 ± 0.5 mm/month) and control (1.3 ± 0.7 mm, 0.6 ± 0.3 mm/month) groups were significantly different ($p=0.117$, 0.041). For the anchorage unit, the amount and rate of second molar mesial tipping between the MIB ($1.8 \pm 0.9^\circ$, $0.8 \pm 0.2^\circ$ /month) and control ($4.2 \pm 2.5^\circ$, $1.8 \pm 0.9^\circ$ /month) groups were significantly different ($p=0.008$, 0.004). The amount and rate of second molar mesialization between the MIB (0.6 ± 0.3 mm, 0.3 ± 0.1 mm/month) and control (2.1 ± 0.9 mm, 1.0 ± 0.2 mm/month) groups were significantly different ($p=0.000$, 0.000). The amount and rate of second molar intrusion between the MIB (0.7 ± 0.3 mm, 0.3 ± 0.2 mm/month) and control (1.8 ± 0.9 mm, 0.8 ± 0.3 mm/month) groups were significantly different ($p=0.002$, 0.000). OE with the MIB efficiently uprights the MI8s and reinforces dental anchorage, thus avoiding undesirable dental movement.

Keywords: Dental anchorage, Orthodontic extraction, Third molar, Uprighting

Received Date: Jun 4, 2020

Revised Date: Jun 23, 2020

Accepted Date: Aug 10, 2020

doi: 10.14456/jdat.2021.5

Correspondence to:

Eduardo Yugo Suzuki, Department of Orthodontics, Faculty of Dentistry, Bangkokthonburi University, 16/10 Leabklongtaweewatana Rd., Taweewatana District, Bangkok 10170 Tel. +66-53-274420, E-mail: eduardo.suz@bkkthon.ac.th

Introduction

The surgical removal of impacted mandibular third molars (MI8s) is a very common surgical procedure.¹⁻³ Patients are often referred for the surgical removal of MI8s for several orthodontic reasons, such as preparation for molar

distalization,⁴ preparation for bilateral sagittal split osteotomy,⁵ and the prevention of late mandibular incisor crowding.⁶ However, the risks and complications involved in this procedure cannot be completely avoided.⁷

chosen based on the following inclusion criteria: 1) good general health; 2) good oral hygiene and healthy periodontium; 3) no use of medications affecting tooth movement or contraindicated for surgery; 4) non-smoking habit; 5) non-carious mandibular third molars and adjacent second molars; 6) no opposing tooth obstructing the path of the third molar uprighting; 7) anchorage teeth (mandibular first molars, second molars and second premolars) present with good contacts and with no spacing or crowding; 8) having enough surface area for orthodontic devices to be attached to MI8 without using invasive methods, such as flap opening or bone removal; and 9) mesio-angulated and partially erupted third molars with Class I or II impaction and depth A or B according to the Pell & Gregory classification³⁹ and the Winter classification.⁴⁰ Approval for the use of the MIB for research activities was granted by the Human Ethics Committee, Faculty of Dentistry, Bangkok Thonburi University (approval number: 15/2018). Informed consent was obtained from all participants.

Methods

Twenty-four MI8s, planned for OE, were divided into two groups: MIB and control groups. In the MIB group, 12 mesio-angulated and partially erupted MI8s were uprighted using the Smart Springs connected to the posterior teeth with anchorage reinforcement provided by the MIB. Another 12 mesio-angulated and partially erupted MI8s, served as controls, were uprighted using the Smart Springs with no anchorage reinforcement of posterior teeth. All MI8s in both groups were removed by simple extraction after the uprighting process.

MIB and Smart Spring

The MIB consisted of 0.019" x 0.025" stainless steel wire welded to the metal brackets of posterior teeth for reinforced anchorage (Figure 1A) and the Smart Spring consisted of a 0.017" x 0.025" stainless steel wire, bent to form a hook and a helical loop at the mesial and the distal ends, surrounded by a closed coil spring, a 150 gram-open NiTi coil spring and a movable hook at the mesial end (Fig. 1B).

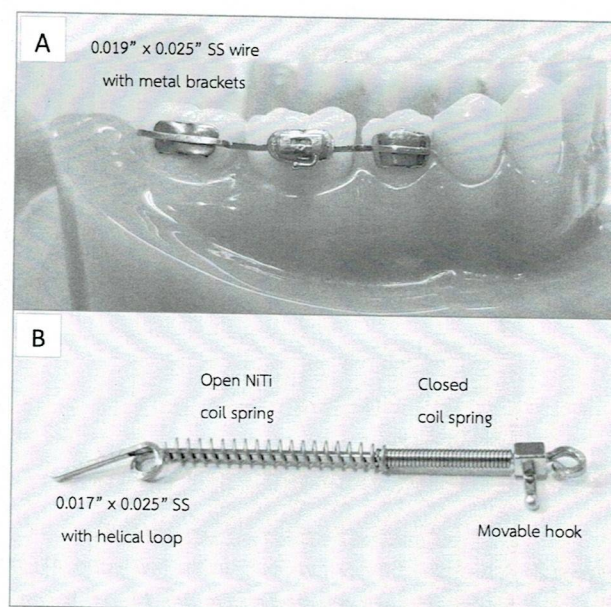


Figure 1 A) Composition of the MIB for reinforced dental anchorage. B) Composition of the Smart Spring

Activation of the Smart Spring

The helical loop at the distal end was adjusted and inserted into a buccal tube on the MI8, while the movable hook at the mesial end was activated and connected to the posterior teeth with the MIB reinforcement in the MIB group (Fig. 2).

Or without the MIB in the control group, the movable hook at the mesial end of the Smart Spring was activated and connected to the individual first molar (Fig. 3).

Activation of the Smart Spring generates a total of 200 g of force (50 g controlled tip-back force from tip-back bending at the distal end and 150 g distalizing force from the open NiTi coil spring application) to upright the MI8. The passive and activated stages of the Smart Spring are illustrated in Figure 4.

Monthly re-activation of the Smart Spring was performed by re-adjusting the tip-back bending at the distal end providing 50 g controlled tip-back force to gain adequate tooth movement of uprighting for removal by simple extraction, based on the clinical judgment of an experienced oral surgeon.

Assessment of the Movement of Moving Unit and Anchorage Unit

Lateral cephalograms and panoramic radiographs were taken at the initial (T0) and by the end of the MIB uprighting (T1). Altered movement and angulation of 24

MIBs (moving unit) and adjacent M7s (anchorage unit) in both groups were monitored and assessed using T0 and T1 radiographs, and Smart'n Ceph MIB v1.1 software (Y&B Products, Chiangmai, Thailand), to evaluate the movement of the moving unit and the anchorage unit (Fig. 5).

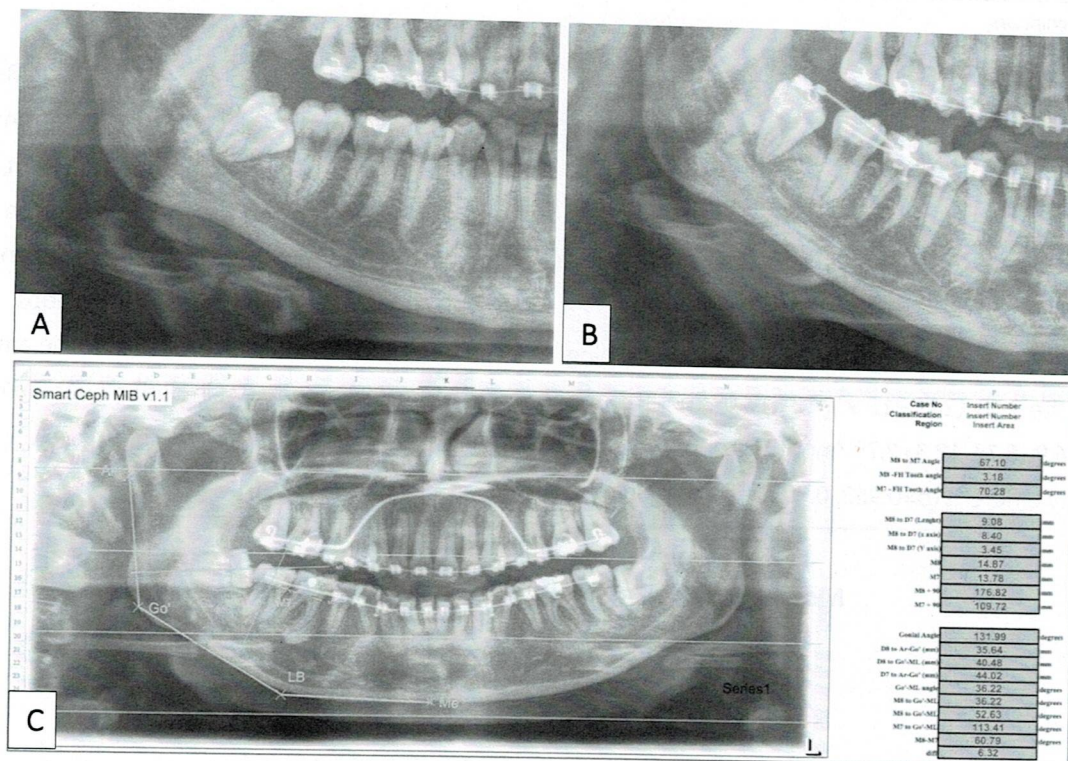


Figure 5 The assessment of changes in position and angulation of the MIBs and M7s using pre- and post-operative panoramic radiographs. A) before MIB uprighting, B) uprighted tooth after completed activation, and C) Smart'n Ceph MIB v1.1 software

The position of the patients was adjusted and verified to decrease positioning errors in panoramic radiography, as previously described.⁴¹ Using the mandibular plane as a reference line,⁴² the angulation changes in M7s were obtained from the altered M7 tooth axis, and the position changes in the MIBs and M7s were measured from the tooth displacement.

Statistical Analysis

SPSS 23.0 software (SPSS Inc., Chicago, IL, USA) was used for all statistical analyses. The average age of participants and the MIB initial impaction angulation were compared between the MIB and control groups using the independent *t*-test. The proportion of gender in both groups was compared using the Chi-square test. The average movement of the moving unit and the anchorage unit were compared between

the two groups. Significance was established at $P < 0.05$.

Five randomly selected panoramic radiographs (20% of the participants) were remeasured one month later by the same examiner to assess reliability. The intraclass correlation coefficients showed high interobserver reliability ranging from 0.916-0.998 for linear measurement and 0.999 for angular measurements.

Results

The age of patients between the MIB and control groups was not significantly different ($p=0.336$). The duration of OE between both groups was not significantly different ($p=0.832$). There was also no significant difference ($p=0.613$) between the initial impaction angulation of the MIBs in the MIB and control groups (Table 1).

Comparison of the Movement of Anchorage Unit (M7s) Between Groups

The amount and rate of M7 mesial tipping between the MIB ($1.8 \pm 0.9^\circ$, $0.8 \pm 0.2^\circ/\text{month}$) and control ($4.2 \pm 2.5^\circ$, $1.8 \pm 0.9^\circ/\text{month}$) groups were significantly different ($p=0.008$, 0.004). The amount and rate of M7 mesialization between the MIB (0.6 ± 0.3 mm, 0.3 ± 0.1 mm/month) and control (2.1 ± 0.9 mm, 1.0 ± 0.2 mm/month) groups were significantly different ($p=0.000$, 0.000). The amount and rate of M7 intrusion between the MIB (0.7 ± 0.3 mm, 0.3 ± 0.2 mm/month) and control (1.8 ± 0.9 mm, 0.8 ± 0.3 mm/month) groups were significantly different ($p=0.002$, 0.000). The amount and rate of M7 movement in both groups are illustrated in Figure 6.

Discussion

This study provided a minimally invasive technique: the OE of mesio-angulated and partially erupted third molars using the dental anchorage device. With the dental anchorage, there are no complications and risk of root damage from the miniscrew implant placement procedure. OE with dental anchorage also is simpler, less invasive, and cheaper than with skeletal anchorage. All participants with mesio-angulated and partially erupted third molars with Class I or II impaction and depth A or B according to the Pell & Gregory classification³⁹ and the Winter classification⁴⁰ were included to perform the OE without surgical operation or any invasive procedure. The mesio-angulated and partially erupted third molar is the most common tooth impaction and is often referred for removal due to the increased risk of pericoronitis and the increased incidence of caries on the adjacent second molars.³²⁻³⁵ Moreover, bone defects at the distal aspect of adjacent second molars and other complications are more likely to occur after the surgical removal of mesioangular MIBs.^{10,38} For these reasons, mesio-angulated and partially erupted third molars were selected to be the participants in this study.

Previous studies have offered many techniques and devices to perform the OE of MIBs.¹⁷⁻²⁹ Most of them were case reports and showed successful results of OE

to avoid the complications of the surgery, especially IAN injury.^{17,18,20-26,43} Moreover, OE also decreases the risk of post-surgical periodontal defects by promoting periodontal healing and bone formation at the distal aspect of the second molar.^{20,25} However, the performance of uprighting devices and the dental anchorage situation, which are important for orthodontic treatment planning, have never been investigated. Thus, this study examined the performance of the MIB and evaluated the dental anchorage loss.

Although the successful OE of MIBs in the present study was similar to Bonetti²⁰ and Wang,²² the results also demonstrated that the dental anchorage loss in the control group was significantly greater than in the MIB group. In the control group, since the uprighting forces were delivered directly to the mandibular first molars through the conventional orthodontic appliances, an undesirable dental mesial drift, and intrusion, with consequent anchorage loss was observed. Such problems might be minimized by anchoring all posterior teeth as a large and single dental unit to resist the uprighting forces.

On the other hand, in the MIB group, the anchorage reinforcement was obtained by connecting the posterior teeth with the aid of the MIB, thus creating a single and large dental unit.⁴⁴ Moreover, the rigidity of MIB increased the total posterior unit resistance against the uprighting force application in all three planes.

Moreover, the mesial movement of M7s was significantly greater in the control group than in the MIB group, whereas less distal movement of MIBs was observed in the control group. This finding implies that the greater the mesial movement of M7s in the control group, there was less need for distal movement of MIBs to gain space for MIB uprighting.

In this study, the amount and rate of the MIB movement indicate that there was tooth displacement in an upright direction using the MIB device. The orthodontic force was applied to MIBs until the MIBs could be atraumatically removed by simple extraction. The average duration of uprighting being approximately two months which was shorter than previous studies.¹⁷⁻²⁹ The Smart

28. Ramaraj PN. Orthodontic extraction: the riskless extraction of the impacted lower third molars close to the mandibular canal. *J Oral Maxillofac Surg* 2008;66(6):1317; author reply
29. Nienkemper M, Ludwig B, Kanavakis G, Pauls A, Wilmes B, Drescher D. Uprighting Mesially Impacted Lower Third Molars with Skeletal Anchorage. *J Clin Orthod* 2016;50(7):420-6.
30. Kravitz ND, Kusnoto B, Hohlt WF. A simplified stent for anterior miniscrew insertion. *J Clin Orthod* 2007;41(4):224-6.
31. Chang HP, Tseng YC. Miniscrew implant applications in contemporary orthodontics. *Kaohsiung J Med Sci* 2014;30(3):111-5.
32. Miclotte A, Franco A, Guerrero ME, Willems G, Jacobs R. The association between orthodontic treatment and third molar position, inferior alveolar nerve involvement, and prediction of wisdom tooth eruption. *Surg Radiol Anat* 2015;37(4):333-9.
33. Bello SA, Adeyemo WL, Bamgbose BO, Obi EV, Adeyinka AA. Effect of age, impaction types and operative time on inflammatory tissue reactions following lower third molar surgery. *Head Face Med* 2011;7:8.
34. Falci SG, de Castro CR, Santos RC, de Souza Lima LD, Ramos-Jorge ML, Botelho AM, et al. Association between the presence of a partially erupted mandibular third molar and the existence of caries in the distal of the second molars. *Int J Oral Maxillofac Surg* 2012;41(10):1270-4.
35. White RP, Jr., Proffit WR. Evaluation and management of asymptomatic third molars: Lack of symptoms does not equate to lack of pathology. *Am J Orthod Dentofacial Orthop* 2011;140(1):10-6.
36. Bui CH, Seldin EB, Dodson TB. Types, frequencies, and risk factors for complications after third molar extraction. *J Oral Maxillofac Surg* 2003;61(12):1379-89.
37. Huang GJ, Rue TC. Third-molar extraction as a risk factor for temporomandibular disorder. *J Am Dent Assoc* 2006;137(11):1547-54.
38. Nguyen E, Grubor D, Chandu A. Risk factors for permanent injury of inferior alveolar and lingual nerves during third molar surgery. *J Oral Maxillofac Surg* 2014;72(12):2394-401.
39. Pell GJ GB. Impacted mandibular third molars: classification and modified techniques for removal. *Dent Digest* 1933;39(9):330-8.
40. GB W. Impacted mandibular third molars. St Louis: American Medical Book Co.; 1926.
41. Kaviani F, Johari M, Esmaili F. Evaluation of common errors of panoramic radiographs in tabriz faculty of dentistry. *J Dent Res Dent Clin Dent Prospects* 2008;2(3):99-101.
42. Kim DM, Park KD, Kwon OW. Assessment of mesiodistal tooth angulation on the panoramic radiograph. *Clinical Orthodontics and Research* 2000;3(3):153-4.
43. Montecchi M, Incerti Parenti S, Checchi V, Palumbo B, Checchi L, Alessandri Bonetti G. Periodontal healing after 'orthodontic extraction' of mandibular third molars: a retrospective cohort study. *Int J Oral Maxillofac Surg* 2014;43(9):1137-41.
44. Proffit WR, Fields HW, Sarver DM. Contemporary orthodontics. 5th ed. St. Louis, Mo.: Mosby Elsevier; 2013. p. 297.