

ประสิทธิผลของการเคลื่อนฟันโดยใช้เทคนิคการผ่าตัดกระดูกที่บร้อมการปลูกถ่าย  
กระดูกและโกรทแฟคเตอร์เข้มข้น

EFFECTIVENESS OF AUGMENTED CORTICOTOMY ASSISTED  
ORTHODONTICS, USING CONCENTRATED GROWTH FACTOR

สุชานาฏ วิเศษศิริ<sup>1</sup>, เอดวาร์โด ยูโก ซูซูกิ<sup>2</sup>, บุญสิวา ซูซูกิ<sup>2</sup>,  
ทองนารถ คำใจ<sup>2</sup>

Suchanard Visetsiri<sup>1</sup>, Eduardo Yugo Suzuki<sup>2</sup>, Boonsiva Suzuki<sup>2</sup>,  
Thongnard Kumchai<sup>2</sup>

<sup>1</sup>นักศึกษาปริญญาโท<sup>2</sup>อาจารย์ คณะทันตแพทยศาสตร์ มหาวิทยาลัยกรุงเทพมหานครธนบุรี, โทรศัพท์ 0-5327-4420

Email: suchanard\_prang@hotmail.com

### บทคัดย่อ

เทคนิคการผ่าตัดกระดูกที่บร้อมกับปลูกถ่ายกระดูกเพื่อการรักษาทันตกรรมจัดฟัน (เอซีเอโอ) สามารถลดเวลาในการรักษาทางทันตกรรมจัดฟันและเพิ่มความหนาของกระดูกขาฟัน อย่างไรก็ตามประสิทธิภาพของเทคนิคเอซีเอโอร่วมกับการใช้โกรทแฟคเตอร์เข้มข้น (ซีจีเอฟ) ยังไม่เคยมีการศึกษามาก่อน ซึ่งซีจีเอฟประกอบด้วยกลุ่มสัญญาณที่สำคัญในกระตุ้นการเจริญเติบโตและสามารถใส่ไปในบริเวณที่ต้องการ การศึกษานี้มีเป้าหมายเพื่อที่จะหาการลดลงของดัชนีการซ้อนเกของฟันของ Little ในแต่ละช่วงเวลาหลังการทำเทคนิคเอซีเอโอร่วมกับการใช้ซีจีเอฟ โดยผู้ป่วยแปดรายที่ตรงกับเกณฑ์การคัดเลือกของวิจัยนี้จะได้รับการรักษาทางทันตกรรมจัดฟันเป็นเวลา 1 เดือนและผ่าตัดด้วยเทคนิคเอซีเอโอ ได้เก็บข้อมูลโดยใช้รูปแบบจำลองฟันสามมิติเพื่อหาดัชนีการซ้อนเกของฟัน ก่อนการผ่าตัด, 1 สัปดาห์, 1 เดือน, 3 เดือน, 6 เดือน, 1 ปี หลังการผ่าตัด จากนั้นบันทึกภาวะแทรกซ้อนหลังการผ่าตัดและทำแบบสอบถามเรื่องความเจ็บปวดและความพึงพอใจ จากการเก็บข้อมูลนำมาแปลผลทางสถิติโดยใช้สถิติ Friedman test ตามด้วยการเปรียบเทียบเชิงคู่ พบว่าจากรายงานผู้ป่วยทั้ง 8 ราย พบการลดลงของดัชนีการซ้อนเกของฟัน ตั้งแต่สัปดาห์แรกและค่อยๆ ลดลง ตามลำดับที่ 1 เดือน, 3 เดือน, 6 เดือน และ 1 ปีหลังการผ่าตัด ทั้งนี้ผู้ป่วย 7 ใน 8 รายพึงพอใจกับผลลัพธ์ของการรักษาและไม่พบภาวะแทรกซ้อนรุนแรง สรุปได้ว่าเทคนิคนี้มีประสิทธิผลในผู้ป่วยอายุมากและมีโรคปริทันต์

**คำสำคัญ:** ผ่าตัดกระดูกที่บร้อมกับปลูกถ่ายกระดูกเพื่อการรักษาทันตกรรมจัดฟัน, การเร่งความเร็วการเคลื่อนที่ของฟัน, ซีจีเอฟ

### Abstract

Augmented Corticotomy Assisted Orthodontics (ACAO) can reduce treatment time and increase alveolar bone width. However, the effect of ACAO combined with concentrated growth factor (CGF), which can deliver growth factors to the site of

application, has never been evaluated. Therefore, the aim of this study is to determine the reduction of Little's irregularity index before surgery, one week after surgery, one month after surgery, three months after surgery, six months after surgery, one year after surgery. The complications as well as the patient's satisfaction and pain were recorded. The data were analyzed by Friedman test followed by pairwise comparison in related sample (paired Wilcoxon signed-rank test). From the results, first week after surgery, application of CGF in ACAO showed significant reduction in Little's irregularity index which gradually decreased after one month, three months, six months and one year. Seven from 8 patients were satisfied with the results of treatment. Moreover, there was no severe complication. In conclusion, this technique was found to be effective in adult patient with periodontal disease.

**Keywords:** Augmented Corticotomy Assisted Orthodontics, accelerated tooth movement, Concentrated Growth Factor

### **Introduction**

Recently, different methods have been suggested for reducing orthodontic treatment time (Nimeri, Kau, Abou-Kheir, & Corona, 2013). Several approaches have been proposed for increasing the rate of tooth movement. Surgically assisted orthodontic tooth movement has been used since the 1800s. Corticotomy-facilitated tooth movement can reduce orthodontic treatment time and allow a predictable outcome of treatment in older patients (W. Wilcko & Wilcko, 2013). Moreover, Amit, Kalra, Pankaj, Suchinder, & Parul, 2012 explained that periodontally-accelerated osteogenic orthodontics (PAOO) can reduce treatment time, increase alveolar bone width, increase post-treatment stability, and decrease the amount of apical root resorption. In this study, Augmented Corticotomy Assisted Orthodontics (ACAO) will be used with concentrated growth factor (CGF), which is a new growth factor, developed by Sacco, 2006. CGF improves the thickness and promotes the healing of soft tissue (Ying, Chen, & Luo, 2017). As ACAO can increase the rate of tooth movement, and CGF is effective in bone formation, this study is designed to determine the overall effectiveness of ACAO combined with CGF.

### **Objective and Hypothesis**

1. To evaluate the length of orthodontic treatment time using ACAO combined with CGF.
2. To evaluate patient satisfaction and pain with the ACAO combined with CGF.

## **Review of Literatures**

### **Adult orthodontics**

Adult patients usually require additional treatment other than orthodontic treatment alone and comprehensive treatment involving multidisciplinary treatment approach. Quality of periodontal and restorative treatments can be improved by correcting the malocclusion and the treatment outcomes can provide esthetic benefits also (Ahmed Meeran, 2012). Various factors must be considered for treating adult patients including psychosocial factors, perio-restorative problems, age related considerations, lack of growth potential, aging of tissues, vulnerability to root resorption and vulnerability to temporomandibular disorder (Bagga, 2010).

### **Accelerated tooth movement**

The duration of orthodontic tooth movement is influenced by many factors (Mavreas & Athanasiou, 2008). It has been suggested that a regional acceleratory phenomenon (RAP) can help accelerate orthodontic tooth movement (Wilcko, Ferguson, Makki, & Wilcko, 2015). Wilcko et al., 2009 suggested that rapid tooth movement occurring after corticotomy may be due to a demineralization-remineralization process that produces a regional acceleratory phenomenon (RAP) of bone remodeling. The RAP begins within a few days of injury, peaks at one to two months, usually last four months in bone and may take 6 to more than 2 years to subside. RAP facilitates orthodontic tooth movement by reducing regional bone density and accelerating bone turnover.

### **Concentrated growth factor (CGF)**

CGF is a new generation platelet derivative which consist of autologous osteoinductive platelet growth factors and an osteoconductive fibrin matrix. This can obtain from blood samples and standardized separation protocol, by a specific centrifuge (Medifuge; Silfradent Srl, Sofia, Italy) (Kavitha & Kathiravan, 2018). In the CGF centrifuge technique, the red phase consists of concentrated red and white blood cells, platelets and clotting factors (Mansour & Kim, 2010). The mechanism involves high quantities of growth factors in the platelets which can stimulate cell proliferation.

### **Patient's satisfactory and pain**

The treatment option of corticotomy-assisted orthodontics was unpopular because of patient's fear from pain and surgery (Zawawi, 2015). A study reported that half of the patients experienced severe pain during meals on the day after corticotomy (Al-Naoum, Hajeer, & Al-Jundi, 2014). However, the pain gradually receded within the

next week, while approximately 60% to 70% of patients reported no pain or only mild discomfort. Post-surgical pain completely disappeared within a 7 to 10 days period (Basu, Baumgaertel, Wu, & Kopchick, 2017; Viwattanatipa & Charnchairerk, 2018; W. M. Wilcko, Wilcko, Bouquot, & Ferguson, 2001).

Visual analogue scales (VAS) have been used in clinical and research settings since the 1920's (Wewers & Lowe, 1990). These scales have been used in the social and behavioral sciences to measure a variety of subjective phenomena. A VAS is a straight line which are labeled as the extreme boundaries of the sensation, feeling, or response to be measured. Subjects respond to the VAS by placing a mark through the line at a position which best represents their current perception of a given phenomenon between the labeled extremes. From previous studies, VAS can also use to record the patient's satisfaction (Magro-Filho et al., 2015 & Bremerich, 2010).

### **Complications**

The oral cavity has a large number of organisms that promotes bacterial growth which can cause infection in a surgical region and delay normal wound healing. Surgical site infection are common complications following oral surgery. A study found that for patient who experience prolonged operation duration are significant risk factors for postoperative complications (Shigeishi, Ohta, & Takechi, 2015). Accidental and operative trauma produce injury to blood vessels and bone, causing the hemorrhage. Surgical trauma can be reduced by handling soft and hard tissue with the greatest care. The tearing of tissue should be avoided. Tissue should be severed from its attachment by sharp dissection. Blunt dissection may be used when tissue is being separated, but only to a point at which the tissue is not likely to be torn (Antioch, 1959). Flap advancement is required as a part of Periodontally- Accelerated Osteogenic Orthodontic treatment. Failure to attain tensionless closure may result in a soft tissue dehiscence along the incision line that can cause a poor outcome and/or post-operative complications (Greenstein, Greenstein, Cavallaro, Elian, & Tarnow, 2009).

### **Conceptual Framework**

Different methods have been suggested for reducing orthodontic treatment time. Of these, none of them showed the satisfied clinical outcome due to the loss of alveolar bone during decortication process contributing to periodontal problems. In the ACAO technique is the treatment with corticotomy-facilitated bone augmentation approach but the bone augmentation can dislodge. To overcome this problem, CGF mixed with particulate bone powder to make sticky bone and CGF membrane will be

added after bone graft. Therefore, this study aimed to develop ACAO combined with CGF technique and evaluate the overall effectiveness of this technique.

## **Research Methodology**

### **Studied Samples**

Eight patients who follow the inclusion criteria were selected from the Orthodontic Clinic, Faculty of Dentistry, Bangkokthonburi University. The inclusion criteria were as followings; adult patients, thin labial plate, thin gingival biotype, controlled mild to moderate periodontitis. The exclusion criteria were as followings; smoking patient, patient with diabetes, devitalized area within bone, long term use of anti-inflammatory drugs (NSAIDs) and corticosteroid during the study, use of bisphosphonate drugs before and during the study, active periodontitis, compromised patient with surgical procedure.

Orthodontic process -Bonding with self-ligated bracket (Tomy) and then loading force on 0.016” NiTi (Sentalloy Tomy International Inc.) for at least 1 month. Then immediately loading force on 0.016” NiTi after the surgery and activating every month.

Surgery process by an oral surgeon -Getting 40-60 cc of patient venous blood to prepare CGF using centrifuge (Medifuge, Sil- fradent srl, Sofia, Italy). After full-thickness mucoperiosteal flap opening, corticotomy was performed by cutting the vertical line 2-3 mm below the bony crest, 2 mm above the root apex. After that, connecting each vertical line with horizontal line to make a perforation for a cortical bone layer, following with the covering of sticky bone and CGF membrane respectively. The data were collected by

1. Measurement of the Little’s irregularity index with digital model in Orthoanalyzer Program for evaluation of reduce in crowding before surgical procedure, after surgical procedure 1 week, 1 month, 3 months, 6 months and 1 year. By measuring the linear distance from anatomic contact point to adjacent anatomic contact point of anterior teeth, the sum of five measurements representing the Little’s irregularity Index.
2. Created questionnaires to record patient satisfaction’s data and pain score (VAS score)
3. Recording the complication that occurred after treatment.

## Statistical Analysis

Descriptive statistics including mean and standard deviation was used to represent the general characteristics of 8 samples in this study. Additionally, to evaluate the effectiveness of the ACAO combined with CGF, the reduction in Little's irregularity index in each arch in different period of time in 8 samples was analyzed by Friedman test followed by pairwise comparison in related sample (paired Wilcoxon signed-rank test).

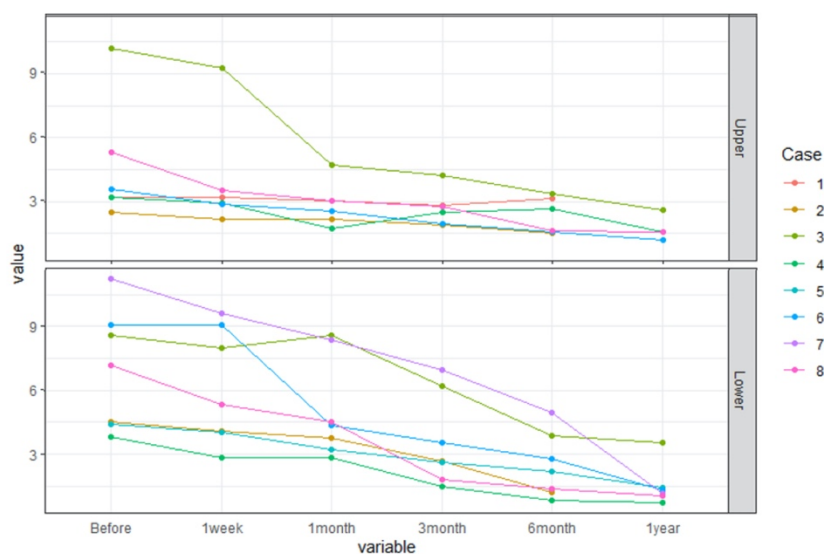
## Research Results

### General Characteristics

The majority of samples were male (6 from 8 cases) with average age of patients at 46.5 years old ranging from 37 to 59 years old. Also, most samples underwent the experiment on both maxillary arch and mandibular arch (62.5 %), followed by mandibular arch (25.0 %) and maxillary arch (12.5 %).

### ACAO Combined with CGF Evaluation

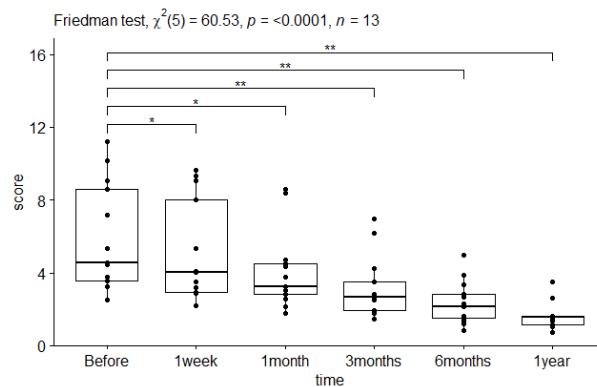
The effectiveness of ACAO combined with CGF was primarily investigated by measuring the Little's irregularity index across period of time including before surgery, 1 week after surgery, 1 month after surgery, 3 months after surgery, 6 months after surgery and 1 year after surgery. Figure 1 shows that the overall trend of Little's irregularity index continues reducing from after surgery to one year in both maxillary arch (upper) and mandibular arch (lower) in all patients as expected.



**Figure 1:** The trend of the Little's irregularity index in the upper and lower with repeated measure in 8 samples.

In order to support the decreasing trend of the Little's irregularity Index in Figure 1, Friedman test confirmed that the overall trend was statistically significant as

expected. ( $\chi^2(5) = 60.53, p < 0.0001, n = 13$ ) as shown in the figure 2. The Little's irregularity index before surgery ( $4.54 \pm 2.97$ ) was more than those of one week ( $4.04 \pm 2.79$ ), 1 month ( $3.22 \pm 2.15$ ) and 3 months ( $2.69 \pm 1.68$ ) after receiving the ACAO combined with CGF (paired Wilcoxon signed-rank test, p-value Bonferroni correction method  $< 0.05$ ). After that, the highly statistically significant difference was subsequently observed in 6<sup>th</sup> month ( $2.16 \pm 1.21$ ). and one year ( $1.55 \pm 2.10$ ), compared with reference index score ( $4.54 \pm 2.97$ ) (paired Wilcoxon signed-rank test, p-value Bonferroni correction method  $< 0.01$ ).



**Figure 2:** The comparison of the Little's irregularity index from before surgery to one year in eight samples. \*= $p < 0.05$ , \*\*= $p < 0.01$

### Satisfaction and Complication

After Surgery, the majority of samples were satisfied with the treatment with high satisfaction score up to 8 points (87.5 %) while moderately satisfaction (4 -7 points) accounted for 12.5 percent of the total. In addition to satisfaction score, 62.5 percent of samples experienced high pain score ranging from 7 to 10 points, but the remaining (37.5 %) was between 0 and 3 points. Furthermore, the complications of most samples equally underwent edema and flap dehiscence (25.0 %) followed by hematoma (37.5 %) while 37.5% experienced none of any complication.

### Discussion

From our results, this technique can relieve crowding in only six months after surgical procedure, similar to the previous reports among the various methods of accelerating treatment. Corticotomy has become very popular in the recent years due to its effectiveness (M. T. Wilcko et al., 2015). It is based on the "Regional Acceleratory Phenomenon (RAP)", where an injury to bone causes a rapid outburst of a localized remodelling which accelerates the healing process (Verna, 2016). W. M. Wilcko et al., 2001 suggested that RAP in humans begins within a few days of surgery, typically peaks

at 1 to 2 months, and may take from 6 to more than 24 months to subside. Our results showed that the reducing in regularity index was higher in first week than other period of treatment. The Little's irregularity index started reduction significantly in first week after surgery then gradually reduced. Besides, the RAP may continue to 1 year after surgery.

From Wilcko et al., 2001 the PAOO technique was done in non-extraction orthodontics for de-crowding with normal orthodontic forces and demonstrated dramatic decreases in treatment times and an increased thickness of alveolar bone. But in this report, we performed in both non-extraction and extraction cases and different orthodontic mechanics in each case. Therefore, the result varied in each case but in overall this technique could decrease the severe crowding in 6 months period.

Various factors can affect the quality and rate of orthodontic tooth movement. Age, sex hormones, and occlusal forces can alter the speed of tooth movement by affecting bone density and remodeling (Aljehani & Baeshen, 2018; Mavreas & Athanasiou, 2008). Also, some may believe that type of brackets such as self-ligate bracket can accelerate tooth movement based on the lower friction between brackets and orthodontic arch wire, but recent studies showed that there were no significant differences during orthodontic tooth alignment. In our study, we used self ligate bracket for lower friction to eliminate the unrelated factor (Chen, Greenlee, Kim, Smith, & Huang, 2010).

### **Suggestion and recommendations**

The main limitations of this study are an inadequate sample size in the intervention group. Therefore, the larger sample size is recommended in the further study in order to evaluate the clinical utility of this technique more effectively. Comparison and control group should be added in further study.

### **Conclusion**

Little's Irregularity index, pain, patient satisfactions and complications were focused and compared between each time point. We have shown that this technique successfully reduced the Little's irregularity index in first week and first month of treatment period and subjects were satisfied with the results with less pain after few days and the complications were acceptable.

### **Reference**



- Ahmed Meeran, N. (2012). The Scope and Limitations of Adult Orthodontics. *Indian J Multidiscip Dent*, 2(1),383-387.
- Al-Naoum, F., Hajeer, M. Y., & Al-Jundi, A. (2014). Does alveolar corticotomy accelerate orthodontic tooth movement when retracting upper canines? A split-mouth design randomized controlled trial. *J Oral Maxillofac Surg*, 72(10), 1880-1889.
- Aljehani, D., & Baeshen, H. A. (2018). Effectiveness of the American Board of Orthodontics Discrepancy Index in predicting Treatment Time. *J Contemp Dent Pract*, 19(6), 647-650.
- Amit, G., Kalra, J., Pankaj, B., Suchinder, S., & Parul, B. (2012). Periodontally accelerated osteogenic orthodontics (PAOO)-a review. *J Clin Exp Dent*, 4(5), e292.
- Antioch, R. J. (1959). Hemorrhage in oral surgery. *Oral Surgery, Oral Medicine, J Oral Pathol*, 12(3), 265-276.
- Bagga, D. (2010). Adult Orthodontics Versus Adolescent Orthodontics: An Overview. *J Oral Health Comm Dent*, 4, 42-47.
- Basu, R., Baumgaertel, N., Wu, S., & Kopchick, J. J. (2017). Growth Hormone Receptor Knockdown Sensitizes Human Melanoma Cells to Chemotherapy by Attenuating Expression of ABC Drug Efflux Pumps. *Horm Cancer*, 8(3), 143-156.
- Chen, S. S., Greenlee, G. M., Kim, J. E., Smith, C. L., & Huang, G. J. (2010). Systematic review of self-ligating brackets. *Am J Orthod Dentofacial Orthop*, 137(6), 726 e721-726 e718; discussion 726-727.
- Greenstein, G., Greenstein, B., Cavallaro, J., Elian, N., & Tarnow, D. (2009). Flap advancement: practical techniques to attain tension-free primary closure. *J Periodontol*, 80(1), 4-15.
- Kavitha, P. D. M., & Kathiravan, D. S. (2018). Concentrated Growth Factor - Review. *J Pharm Biomed Anal*, 7(03), 13-20.
- Magro-Filho, O., Goiato, M. C., Oliveira, D. T. N., Martins, L. P., Salazar, M., Medeiros, R. A. D., & Santos, D. M. D. (2015). Evaluation of Patients' Satisfaction after Class III Orthognathic Surgery. *J Chin Diagn Res*, 9(10), ZC23-ZC27.
- Mansour, P., & Kim, P. (2010). Use of Concentrated Growth Factor (CGF) in implantology. *Aust Dent Pract*, 21(2), 162-176.
- Mavreas, D., & Athanasiou, A. E. (2008). Factors affecting the duration of orthodontic treatment: a systematic review. *Eur J Orthod*, 30(4), 386-395.
- Nimeri, G., Kau, C. H., Abou-Kheir, N. S., & Corona, R. (2013). Acceleration of tooth movement during orthodontic treatment-a frontier in orthodontics. *Prog Orthod*, 14(1), 42.
- Sacco, L. (2006). Lecture, International academy of implant prosthesis and osteoconnection. *Lecture*, 12, 4.
- Shigeishi, H., Ohta, K., & Takechi, M. (2015). Risk factors for postoperative complications following oral surgery. *J Appl Oral Sci*, 23(4), 419-423.
- Verna, C. (2016). Regional Acceleratory Phenomenon. *Front Oral Biol*, 18, 28-35.
- Vivattanatipa, N., & Charnchairerk, S. (2018). The effectiveness of corticotomy and piezocision on canine retraction: A systematic review. *Korean J Orthod*, 48(3), 200-211.
- Wewers, M. E., & Lowe, N. K. (1990). A critical review of visual analogue scales in the measurement of clinical phenomena. *Res Nurs Health*, 13(4), 227-236.

- Wilcko, M. T., Ferguson, D. J., Makki, L., & Wilcko, W. M. (2015). Keratinized Gingiva Height Increases After Alveolar Corticotomy and Augmentation Bone Grafting. *J Periodontol*, *86*(10), 1107-1115.
- Wilcko, M. T., Wilcko, W. M., Pulver, J. J., Bissada, N. F., & Bouquot, J. E. (2009). Accelerated osteogenic orthodontics technique: a 1-stage surgically facilitated rapid orthodontic technique with alveolar augmentation. *J Oral Maxillofac Surg*, *67*(10), 2149-2159.
- Wilcko, W., & Wilcko, M. T. (2013). Accelerating tooth movement: the case for corticotomy-induced orthodontics. *Am J Orthod Dentofacial Orthop*, *144*(1), 4-12.
- Wilcko, W. M., Wilcko, T., Bouquot, J. E., & Ferguson, D. J. (2001). Rapid orthodontics with alveolar reshaping: two case reports of decrowding. *Int J Periodontics Restorative Dent*, *21*(1), 9-19.
- Ying, X., Chen, Y., & Luo, N. (2017). The Use of Concentrated Growth Factors and Autogenous Bone for Periodontal Soft Tissue Augmentation and Bone Regeneration: A Case Report. *Electronic J Biol*, *13*(3), 269-273.