

main-content

Ann Maxillofac Surg. 2014 Jul-Dec; 4(2): 162–170.

doi: [10.4103/2231-0746.147110](https://doi.org/10.4103/2231-0746.147110)

PMCID: PMC4293836

Biomechanical comparison of two intraoperative mobilization techniques for maxillary distraction osteogenesis: Down-fracture versus non-down-fracture

[Lili Yang](#), [Eduardo Yugo Suzuki](#), and [Boonsiva Suzuki](#)

Department of Orthodontics and Pediatric Dentistry, Faculty of Dentistry, Chiang Mai University, Chiang Mai, Thailand

Address for correspondence: Dr. Eduardo Yugo Suzuki, Department of Orthodontics and Pediatric Dentistry, Faculty of Dentistry, Chiang Mai University, Suthep Road, Amphur Muang, Chiang Mai 50200, Thailand. E-mail: moc.liamtogh@udmtoguy

Copyright : © Annals of Maxillofacial Surgery

This is an open-access article distributed under the terms of the Creative Commons Attribution-Noncommercial-Share Alike 3.0 Unported, which permits unrestricted use, distribution, and reproduction in any medium, provided the original work is properly cited.

Abstract

article-meta

Purposes:

The purpose of this study was to compare the distraction forces and the biomechanical effects between two different intraoperative surgical procedures (down-fracture [DF] and non-DF [NDF]) for maxillary distraction osteogenesis.

Materials and Methods:

Eight patients were assigned into two groups according to the surgical procedure: DF, $n = 6$ versus NDF, $n = 2$. Lateral cephalograms taken preoperatively (T1), immediately after removal of the distraction device (T2), and after at least a 6 months follow-up period (T3) were analyzed. Assessment of distraction forces was performed during the distraction period. The Mann–Whitney U-test was used to compare the difference in the amount of advancement, the maximum distraction force and the amount of relapse.

Results:

Although a significantly greater amount of maxillary movement was observed in the DF group (median 9.5 mm; minimum-maximum 7.9-14.1 mm) than in the NDF group (median 5.9 mm; minimum-maximum 4.4-7.6

mm), significantly lower maximum distraction forces were observed in the DF (median 16.4 N; minimum-maximum 15.1-24.6 N) than in the NDF (median 32.9 N; minimum-maximum 27.6-38.2 N) group. A significantly greater amount of dental anchorage loss was observed in the NDF group. Moreover, the amount of relapse observed in the NDF group was approximately 3.5 times greater than in the DF group.

Conclusions:

In this study, it seemed that, the use of the NDF procedure resulted in lower levels of maxillary mobility at the time of the maxillary distraction, consequently requiring greater amounts of force to advance the maxillary bone. Moreover, it also resulted in a reduced amount of maxillary movement, a greater amount of dental anchorage loss and poor treatment stability.

Keywords: Distraction force, down-fracture, non-down-fracture

INTRODUCTION

Distraction osteogenesis is a biomechanical process where the application of incremental traction forces leads to new bone formation between the surfaces of osteotomized bone segments that are gradually separated.[1] This technique not only allows increments of new bone, but also allows the stretching of the surrounding soft tissue.[1] Therefore, distraction osteogenesis has become a very important alternative in the treatment of patients with severe maxillary hypoplasia in craniofacial syndromes and cleft-related deformities.[2,3]

Maxillary distraction osteogenesis has been applied successfully for the management of patients with clefts, having several advantages over the conventional orthognathic procedures, advantages such as allowing large amounts of maxillary advancement, thus eliminating the need for bone grafting and reduced rates of relapse.[3] Currently, this technique has been successfully applied with the use of either external or internal distraction devices.[4] In addition, the novel surgical procedure of maxillary anterior segmental distraction osteogenesis[5,6] and the modified method[7,8] have been performed for patients with cleft palate.

Conventional surgical procedures to perform maxillary distraction osteogenesis often involve a Le Fort I complete osteotomy with pterygomaxillary dysjunction, septal dysjunction and careful medial sinus wall separation followed by an intraoperative down-fracture [DF] to achieve the complete mobilization of the maxilla.[9,10] However, the DF is considered a high risk and aggressive procedure since it may induce undesirable fractures extended to the pterygoid plate, sphenoid bone and

cranial base, edema and bleeding.[11] Moreover, in patients with an abnormal bone structure, such as observed in cleft-related patients, the surgical procedure can be more difficult and less predictable.[12] In order to minimize the risk of the surgical procedure and shorten the operation time, the use of maxillary osteotomy without the complete intraoperative DF, also known as the non-DF (NDF) technique has been proposed by several authors.[13,14,15] In the NDF technique, the maxilla is mobilized just enough to ensure that the skeletal osteotomy had been completed.[13] Therefore, the traditional aggressive DF procedure is not fully performed.[13,15]

Some reports have shown that cases treated without DF technique allows for sufficient mobilization of the maxillary bone, consequently providing similar surgical outcomes of cases treated with the conventional DF technique.[15,16]

However, our hypothesis is that by using two different surgical procedures, it may provide different levels of maxillary mobility at the time of the maxillary distraction. As a consequence, it might play an important role in the total amount of force necessary to stretch the surrounding soft and hard structures. Such differences might affect not only the total amount of maxillary movement, but also the amount of dental movement and treatment stability. Moreover, little is known about the biomechanical changes promoted by the application of different surgical protocols.

In recent times, the authors have developed a direct method for measuring the distraction forces during maxillary distraction osteogenesis using a simple mechanism.[17] The direct measurement of maxillary distraction forces provides current information about the mechanical response and thereby, the condition in the distracted structures. Assessment of the forces within the maxillary bone during distraction osteogenesis may lead to a better understanding of the nature and biology of distraction, and help determine the most appropriate distraction protocol to be adopted.[17]

Therefore, the purpose of the present study was to compare the distraction forces and the biomechanical effects between two different intraoperative surgical procedures (DF and NDF) for maxillary distraction osteogenesis.

MATERIALS AND METHODS

This study was carried out on patients who had received treatment with maxillary distraction osteogenesis through the use of a rigid external distraction (RED) (RED system, Martin L.P., Jacksonville, FL, USA) device combined with the twin-track distraction device in an attempt to optimize the distraction procedure and improve patient comfort during

maxillary advancement. A simple mechanism to measure and adjust the tension force on the traction wire was custom-made designed to obtain data, therefore analyzing the behavior of forces applied through maxillary distraction osteogenesis by means of a force gauge as described by Suzuki and Suzuki.[17] This study followed the Declaration of Helsinki on medical protocol and ethics, and the regional Ethical Review Board of Chiang Mai University approved the study.

Eight patients with a variety of dento-alveolar clefts that had been selected to receive maxillary distraction osteogenesis treatment were asked to take part in this study. Criteria for the patient selection were based on the presence of a severe maxillary hypoplasia. Maxillary advancement was performed in nongrowing patients. In none of these patients, alveolar bone grafting had been previously performed.

All patients went through history and clinical examination as well as complete dental and intraoral examination. Clinical photographs, dental models and lateral cephalograms were made preoperatively. Further lateral cephalograms were obtained after the latency period, during the distraction period, after completion of the active period of distraction, and at the completion of the consolidation period. The progression of osteogenesis, the amount of maxillary advancement, and any dento-skeletal relapse was evaluated on the radiographs.

The patients were assigned into two groups according to the surgical procedure they had received. All surgical procedures were performed by the same surgeon. In the first group (DF), six patients, one with bilateral cleft lip and palate (BCLP) and five with unilateral cleft lip and/or palate (UCLP), had the maxillary bone completely mobilized with the intraoperative DF procedure. In the second group (NDF), two patients, one with BCLP and one with UCLP, underwent Le Fort I complete osteotomy without the DF procedure [[Table 1](#)].

Surgical procedure

Surgical procedures were performed under general anesthesia with orotracheal intubation with infiltrative anesthesia of 1% xylocaine with 1:100,000 epinephrine. Incisions were made along the buccal vestibule of the maxilla bilaterally and mucoperiosteal flaps were elevated. All patients underwent complete maxillary Le Fort I complete osteotomy with pterygomaxillary dysjunction, septal dysjunction and careful medial sinus wall separation. The intraoperative DF was performed in six patients to achieve the complete mobilization of the maxilla (DF group). Mobility of the osteotomized maxilla was verified to ensure that all bone resistance was released. The maxilla was completely separated from the pterygoid

plates and perpendicular process of the palatine bone. Neither advancement nor repositioning of the maxilla was performed.

In two patients, in order to minimize the risk of the surgical procedure and shorten the operation time, the intraoperative DF was not performed (NDF group), as described by Yamauchi *et al.*[13] In the NDF technique, the maxilla was mobilized just enough to ensure that the skeletal osteotomy had been completed.[13] Therefore, the pterygomaxillary dysjunction was not completely performed. Furthermore, the distraction trial, to move the maxilla forward as proposed by Yamauchi *et al.* was not performed.

In all patients, the incisions were irrigated and sutured with 3-0 Vicryl. The twin-track arch was mounted on the supporting teeth across the cleft, assisting stabilization of the osteotomized maxillary segments.

Distraction protocol and force measurement

Maxillary distraction osteogenesis was performed after a complete Le Fort I osteotomy, under general anesthesia with orotracheal intubation, using a RED device in combination with a twin-track distractor connected to the dentition[15] and removable intraoral splint[16,17] for anchorage of distraction forces [Figure 1]. A latency period of 4-6 days was observed before initiating distraction.

A simple mechanism to measure and adjust the maxillary distraction forces was specially designed to allow direct measurement of tension force during maxillary distraction osteogenesis as described by Suzuki and Suzuki.[17] The mechanism was connected bilaterally to the traction screws of a RED system in order to analyze the behavior of forces applied through maxillary distraction osteogenesis by means of a force gauge [Figure 2]. In all cases, the maxilla was advanced parallel to the functional occlusal plane. The traction micro-cables replaced the conventional surgical wires in order to optimize the transference of traction forces to the maxillary bone, thereby avoiding the distortion that is observed when traction wires are used.[14] Distraction force can be measured directly by simply pulling on the cable loop. A light sensor was used to identify the minimum distance necessary to unseat the stopper. Distraction force equals the measurement force that is just sufficient to unseat the stopper.

Distraction was performed at the rate of 1.0 mm/day in two increments, respecting a 12 h interval. Measurements were carried out before and after activation using a digital force gauge (Shimpo FGS-50S, Nidec-Shimpo America Corporation, Itasca, IL, USA) during the distraction period. The amount of force being applied was also evaluated daily during the consolidation period.

The duration of the maxillary distraction period was determined clinically and cephalometrically by the severity of the mid-face retrusion and correction of the anterior dental cross-bite [Figure 3]. All patients remained in the hospital during the distraction period. Activation and distraction force measurements were performed by the same orthodontist (EYS). The patients were followed-up daily to assess progression of distraction until the proper overjet, overbite, and relatively stable occlusion were achieved. The device was maintained for 4 weeks for rigid retention after activation was completed. After this period, the cranial portion of the RED device was removed with a small amount of local anesthetic at the scalp pin sites. An additional 4-6 weeks of retention using facial mask elastics was utilized.

Dento-skeletal measurements

Dento-skeletal changes were analyzed using serial sets of lateral cephalograms made in centric occlusion at the following stages: Preoperatively (T1), immediately after removal of the distraction device (T2), and after at least a 6 months follow-up period (T3). Additional radiographies were made during the distraction period to assess the amount of dento-skeletal movement during the activation period. All lateral cephalograms obtained at each interval were traced on acetate paper. The anterior cranial base was used for overall superimposition.

Fifteen skeletal and dental landmarks and three reference planes were identified [Figures

[\[Figures4a](#)

[4a and](#)

[andb\]](#).

[b\]](#). Custom-made digitizer software (Smart Ceph version 9.0 XP, Y and B Products, Chiang Mai, Thailand) was used to perform all linear and angular cephalometric measurements.

An XY coordinate system was constructed on the sella turcica (S). A line parallel to the Frankfort horizontal (FH) plane passing through S was used as the X-axis; a line drawn perpendicular to this plane through S was used as the vertical or Y-axis.[18] The SN line and the XY axis were transferred from T1 to T2, T2 and T3 as accurately as possible by using the anterior cranial base for overall superimposition. The subtraction of the X and Y values for each landmark at each interval was calculated to estimate the horizontal and vertical displacement of the landmarks. The magnification of the cephalograms was 10%. However, no correction was made because all radiographs were made in the same cephalostat with the same object-

film distance. The radiographs were obtained with the lips in the relaxed position.

Skeletal changes

Measurements that indicated the changes and stability in the position of the maxilla were the horizontal, vertical and linear movement of point A (A), and the angle changes including SNA, SNB, ANB, palatal plane-FH and mandibular plane-FH [[Figure 4a](#)].

Dental changes

The perpendicular distances of the maxillary central incisor edge (U1) and root apex (U1r), first molar crown (U6) and furcation (U6r) from the palatal plane (U1/PP mm, U6/PP mm), and the linear distance from posterior nasal spine to central incisor apex (U1r) and first molar furcation (U6r) were measured. The angles between the long axis of the incisors (line through U1 to U1r) and the palatal plane (U1/PP°) and between the long axis of first molar (line through U6 to U6r) and palatal plane (U6/PP°) were measured [[Figure 4b](#)].

Error of the method

The Dahlberg formula was used to determine the standard error for variables in each data set. Five subjects (with T1, T2 and T3 radiographs) were randomly selected. Each radiograph was retraced, superimposed, and re-digitized for the error determination. The error was <0.8 mm for linear skeletal measurements and 1.5° for angular measurements.

Statistical analysis

The statistical analyses were performed using the SPSS program (SPSS Inc., Chicago, IL, USA) on a personal computer. The median, minimum, and maximum of the measurements were calculated. A paired *t*-test was used to compare the treatment changes during the following two periods: (1) The distraction period (T1 vs. T2) and the follow-up period (T2 vs. T3).

The Pearson correlation coefficient was used to determine the correlation between the amounts of maxillary advancement and the distraction force increment during the distraction period (T1 vs. T2) and between the increment of distraction force and the amount of relapse at the follow-up period (T2 vs. T3).

The Mann–Whitney U-test was used to compare the differences in the amount of advancement, the maximum distraction force, and the amount of relapse between the DF and NDF groups. The *P* value for all tests was set at <0.05.

RESULTS

Distraction protocol

Comparisons between the DF and NDF groups during the distraction period (T1-T2) are shown in [Table 2](#).

Although a similar distraction protocol, such as latency, rate of activation and consolidation periods, was adopted for both groups, a significantly larger amount of maxillary movement was observed in the DF group (median 9.5 mm; minimum-maximum 7.9-14.1 mm) than in the NDF group (median 5.9 mm; minimum-maximum 4.1-7.6 mm). The actual rate of skeletal movement was approximately 3 times higher for the DF group (median 0.9 mm/day; minimum-maximum 0.7-1.0 mm/day) than for the NDF group (median 0.4 mm/day; minimum-maximum 0.3-0.4 mm/day). Comparison of the actual ratio of skeletal movement (amount of activation: Amount of movement) was significantly greater for the DF group (median 1: 0.8; minimum-maximum 1: 0.6-1:0.8) than for the NDF group (median 1:0.3; minimum-maximum 1:0.3-1:0.4).

Dento-skeletal changes

Cephalometric analysis, demonstrated a significantly greater change in the value of SNA of the DF group (median 7.5°; minimum-maximum -5.3-9.8°) than of the NDF group (median 4.4°; minimum-maximum -3.5-5.2°). An opposite vector of displacement was observed in the inclination of the palatal plane between the DF and NDF groups. A clockwise rotation of the palatal plane (median 2.5°; minimum-maximum -4.8-6.7°) was observed in the DF group, whereas a counter clockwise rotation was observed (median -8.3°; minimum-maximum -13.2-3.2°) in the NDF group. Moreover, there was a significantly greater change in the value of the mandibular plane in the NDF group (median 3.4°; minimum-maximum 2.6-4.1°) than in the DF group (median -1.1°; minimum-maximum 0.6-2.1°).

In the DF group, U1 (median -5.4°; minimum-maximum -10.8-1.2°) and U6 (median -5.5°; minimum-maximum -11.5-2.0°) were palatally inclined with minimal amounts of dental extrusion of U1 (median 0.8 mm; minimum-maximum -0.1-2.6 mm) and U6 (median 0 mm; minimum-maximum -4.1-1.7 mm). In contrast, in the NDF group, U1 (median 12.6°; minimum-maximum 1.2-24°) was buccally inclined, while U6 (median -1.7°; minimum-maximum -7.5-4.1°) was mesially inclined. A large amount of dental extrusion was observed in U1 (median 3.5 mm; minimum-maximum 1.3-5.7 mm) and U6 (median 1.3 mm; minimum-maximum 0.5-2.1 mm).

Distraction forces

Analysis of forces measured demonstrated significantly greater maximum distraction forces for the NDF group (median 32.9 N; minimum-maximum 27.6-32.8 N) than for the DF (median 16.4 N; minimum-maximum 15.1-24.6 N) group [Figure 5]. Moreover, the NDF group exhibited a significantly greater force increment (median 5.3 N; minimum-maximum 3.9-6.7 N) than did the DF group (median 2.6 N; minimum-maximum 1.9-3.4 N) [Figure 6]. It was also observed that the residual force by the end of the consolidation period (before Halo removal) was greater in the NDF group (median 1.4 N; minimum-maximum 0.8-2.0 N) than in the DF group (median 0.5 N; minimum-maximum 0.3-0.8 N), and there was no statistical significance between groups. However, no significant difference in the amount of force decay between the DF and NDF groups was observed.

Stability

Comparisons of dento-skeletal changes between the DF and NDF groups during the follow-up period (T2-T3) are shown in Table 3.

A significantly greater amount of relapse was observed in the NDF group (median -4.4 mm; minimum-maximum -5.2-3.6 mm) than in the DF group (median -1.6 mm; minimum-maximum -4.2-1.2 mm). Moreover, the percentage relapse in observed in the NDF group (median 72%; minimum-maximum 65-79%) was approximately 3.5 times greater than in the DF group (median 18%; minimum-maximum 13-30%). The SNA values also confirmed the greater amount of relapse in the NDF group (median -1.3°; minimum-maximum -5.8-4.2°) than in the DF group (median 1.9°; minimum-maximum -2.6-0.6°).

Cephalometric analysis also demonstrated a significant difference in the amount and pattern of relapse in the inclination of the palatal plane. In the DF group (median -2.4°; minimum-maximum -3.6-1.8°), a counter clockwise rotation of the palatal plane was observed, whereas in the NDF group (median 7.8°; minimum-maximum 4.5-11.0°) a clockwise rotation was observed. No significant differences in the SNB, ANB or mandibular plane angle were observed between groups. Also, no significant differences in the dental changes between the DF and NDF groups were observed during the follow-up period.

Although large amounts of dental changes were observed in the follow-up period, the differences were not statistically significant.

DISCUSSION

Different intraoperative surgical protocols involving the use of DF and NDF procedures have been applied to maxillary distraction osteogenesis. [9,10,13,15] The main advantage of the NDF over the DF procedure is the reduction of risks and complications, thus reducing surgical time.[13,15] However, little is known about the biomechanical changes and stability promoted by the application of such different surgical protocols. In our study, comparison of distraction forces and the biomechanical effects between these two different intraoperative surgical procedures have been performed.

DOG protocol

Although similar distraction protocol was adopted for both DF and NDF groups, no significant difference was observed in the latency, rate of activation or consolidation periods. However, the activation period was significantly longer for the NDF group (median 17.5 days; minimum-maximum 12-23 days) than for the DF group (median 10.5 days; minimum-maximum 10-18 days). In contrast, the amount of maxillary advancement was significantly greater for the DF group (median 9.5 mm; minimum-maximum 7.9-14.1 mm) than for the NDF group (median 22.5 mm; minimum-maximum 17-28 mm). Therefore, the actual ratio of skeletal movement was approximately 3 times greater for the DF group (median 0.9 mm/days; minimum-maximum 0.7-1 mm/days) than for the NDF group (median 0.35 mm/days; minimum-maximum 0.3-0.4 mm/days). This result indicates that the total amount of maxillary advancement was highly influenced by the type of surgical procedure. The use of DF allowed for a larger amount of movement in a significantly shorter period of time, thus providing more efficient bone movement during distraction. The results of this study contrast with the findings of Yamauchi *et al.*, [13] who reported larger amounts of maxillary advancement (10.0-17.0 mm) in a group of six patients with clefts who underwent maxillary distraction osteogenesis without the intra-operative DF.[13] However, in their study, titanium ret Alkan ention plates were fixed to the lateral walls of the maxilla to allow the intraoperative distraction trial to ensure free movement of the segments.[13] However, in our study, maxillary distraction was performed with a twin-track distraction device, that is essentially a tooth-borne device. Moreover, the intraoperative distraction trial, as suggested by Yamauchi *et al.* was not performed.[14] Therefore, we considered that the intraoperative distraction trial might have played an important role in the amount and quality of movement of maxillary bone during the distraction period.

Several authors have applied a modification of the NDF procedure to create the so-called “minimal DF” technique in an attempt to reduce risks and complications related to the DF technique.[3,19,20] However, there is a lack of information regarding the differences in the distraction outcomes, such as the amount of advancement, stability of changes or amount of force necessary to displace the osteotomized maxillary bone between NDF and DF procedures.

In our study, one patient who underwent NDF required an additional surgical procedure to allow the complete mobilization of the maxilla. The possible cause of the failure was the presence of bone contacts that remained intact at the posterior maxilla. After the remaining bone contacts were eliminated, the maxilla was advanced to the planned position, thus indicating that the complete mobilization of the maxilla plays an important role on the distraction process. This is particularly important considering distraction osteogenesis, since the partial mobilization of the osteotomized maxilla may generate substantial resisting forces that compromise the maxillary advancement, or would require an additional surgical procedure to ensure that the maxilla has been completely mobilized.

A similar result was reported by Alkan *et al.*,[21] who reported the failure of maxillary distraction osteogenesis due to the incomplete mobilization of the maxilla. In their report, although the complete Le Fort I osteotomy, followed by the intraoperative DF, was performed, the maxillary advancement was not possible. A second surgical procedure was necessary to allow complete mobilization of the maxillary bone, to achieve the planned maxillary advancement. Therefore, the complete mobilization of the maxillary bone plays an important role in the final outcomes of the distraction procedure.

Dento-skeletal changes

Analysis of dento-skeletal changes demonstrated significant differences in the amount and direction of the rotation of the osteotomized maxillary bone. In the DF group, a clockwise rotation pattern was observed, whereas a counter clockwise rotation of the maxillary bone was clearly observed in the NDF group. Although it was not possible to confirm the amount or type of bone attachment through radiographic examination, the main explanation for such differences might be attributed to the differences in the bone attachment at the posterior maxilla. In the DF group, the maxillary bone was completely mobilized, consequently allowing the unrestricted down-forward movement of the maxilla at the planned position. In contrast, in the NDF group, the presence of bone contacts at the posterior maxilla or incomplete osteotomies, limited the movement of

the maxilla. And as a consequence, when the distraction force was applied, the partially osteotomized maxilla did not move to the planned down-forward position; instead it moved up-forward.[21] Such undesirable and unplanned movements would lead to unsatisfactory results.

The presence of incomplete osteotomies has also been reported by several authors.[14,16,22] Dolanmaz *et al.*,[23] have observed different types of unpredictable fractures after the DF procedures in a group of cadavers. In their study, the incomplete osteotomies were evaluated using computed tomography scan to identify the areas with incomplete fractures.

Cephalometric analysis also demonstrated significant differences in the amount and direction of dental movement between the DF and NDF groups. In the DF group, palatal inclination of U1 and distal tipping of U6 were observed. In contrast, in the NDF group, buccal inclination of U1 and mesial tipping of U6 were observed. Such contrasting dental movements can be explained by the different amounts of maxillary bone resistance to the movement during the maxillary advancement between the DF and NDF groups. In the DF group, the maxilla was moved down-forward with distraction forces 3 times lower than the forces used to move the maxilla in the NDF group. As a result, palatal tipping of U1 combined with distal tipping of U6 was observed. In the NDF group, since a relatively high amount of force was necessary to advance the maxillary bone, both U1 and U6 were moved mesially, indicating a large amount of dental movement [Figure 7]. It is important to note that although a large amount of force was used in the NDF group, the maxillary bone did not move forward to the planned position.

The results of this study are in accordance with those of Block *et al.*,[22] who investigate the amount of dental anchorage loss associated with the use of tooth-borne distractors. Block *et al.*[24] have demonstrated that some amount of dental anchorage loss is expected when tooth-borne devices are used. However, the pattern of dental changes between the DF and NDF groups observed in our study can be attributed to the different levels of resistance to movement offered by the osteotomized maxillary bone. Such differences in the dental changes indicate that the type of surgical procedure might play an important role in the amount and direction of the dental changes. This can be critically important considering the use of tooth-borne devices. The use of bone-borne distractors, or the use of distractors connected to miniscrew implants, can reduce or avoid undesirable dental effects during distraction osteogenesis. [25,26]

Distraction forces

In this study, the assessment of distraction forces demonstrated significantly greater maximum distraction forces for the NDF group (median 32.9 N; minimum-maximum 27.6-38.2 N) than for the DF group (median 16.4 N; minimum-maximum 15.1-24.6 N). Similarly, the assessment of force increment during the distraction period also confirmed a significantly greater force increment (median 5.3 N; minimum-maximum 3.7-6.7 N) for the NDF group than for the DF group (median 2.6 N; minimum-maximum 2-3.4 N).

The results are in accordance those of a previous study by Suzuki and Suzuki,[15] who assessed the distraction forces necessary to advance the distracted maxillary bone. However, in their study, only completely osteotomized maxillary bone was investigated.[17]

Our results suggest that resisting forces might be generated by the incomplete fracture at the posterior maxilla, thus compromising the complete mobility of the maxillary bone. The presence of such bone contacts that remained intact at the posterior maxilla generates high resisting forces to the movement during the distraction period, consequently limiting the total amount of skeletal movement.[21] Such increase in the movement resistance has also been followed by increments of force during the distraction. This result is a new finding and indicates that the use of different surgical procedures (DF and NDF) provides significant differences in the biomechanical response of the distracted structure.

Analysis of the dento-skeletal changes revealed that there was a significantly greater amount of dental anchorage loss in the NDF group. The greater increments of force during the distraction period led to a more prominent dental anchorage loss. This is particularly important considering the use of tooth-borne devices. Block *et al.*[24] have reported a significant amount of dental movement during distraction using tooth-borne distraction devices.

It was also observed that the amount of residual force by the end of the consolidation period, before removal of the distraction device, was almost 4 times greater in the NDF group (median 14 N; minimum-maximum 0.8-2 N) than in the DF group (median 0.5 N; minimum-maximum 0.3-0.8 N). The result indicates that the distraction force applied to the NDF group was not applied effectively to produce the movement of the maxillary bone; instead, it was stored within the partially osteotomized maxilla throughout the consolidation period. As a consequence, a significant amount of dental anchorage loss was observed in the NDF group.

Stability

Maxillary distraction osteogenesis, despite the large amount of movement, has been described as a relatively stable procedure compared to the conventional osteotomy procedures.[18,27] Moreover, the stability of changes following maxillary distraction osteogenesis has been associated with the amount of advancement,[10] distractor type reference,[3,4,28] facial growth after distraction,[29] and the amount of scar tissues in patients with clefts.[12,30]

However, in our study, a significantly greater amount of relapse was observed in the NDF group (median -4.4 mm; minimum-maximum -5.2-3.6 mm) than in the DF group (median -1.6 mm; minimum-maximum -4.2-1.2 mm). Moreover, the percentage relapse observed in the NDF group (median 72%; minimum-maximum 65-79%) was approximately 3.5 times greater than the DF group (median 18.3%; minimum-maximum 13-30%). The results clearly indicate that the modality of the surgical procedure plays an important role in stability following maxillary distraction osteogenesis.

CONCLUSIONS

This study suggests that the use of two different surgical procedures resulted in significantly different biomechanical responses of the osteotomized maxillary bone. The use of the NDF procedure resulted in lower levels of maxillary mobility at the time of the maxillary distraction, consequently requiring higher amounts of force to advance the maxillary bone. Moreover, it also resulted in reduced amounts of maxillary movement, higher amounts of dental anchorage loss and poor treatment stability.

In a future study, a bone-borne anchorage will be applied to avoid the effect of the Twin-track arch (TT) device on the dento-skeletal changes.

ACKNOWLEDGMENTS

The authors acknowledge the assistance of Dr. M. Kevin O Carroll, Professor Emeritus of the University of Mississippi School of Dentistry, USA, and Faculty Consultant, Chiang Mai University Faculty of Dentistry, Thailand, in the preparation of the manuscript.

This study was supported by grant from the Faculty of Dentistry, Chiang Mai University and grant number RSA 5480029 from the Thailand Research Funding.

Footnotes

back/fn-group

Source of Support: This study was supported by grant from the Faculty of Dentistry, Chiang Mai University and grant number RSA 5480029 from the Thailand Research Funding.

Conflict of Interest: None declared.

REFERENCES

1. Ilizarov GA. The principles of the Ilizarov method. *Bull Hosp Jt Dis Orthop Inst.* 1988;48:1–11. [PubMed: 2840141]
2. Polley JW, Figueroa AA. Rigid external distraction: Its application in cleft maxillary deformities. *Plast Reconstr Surg.* 1998;102:1360–72. [PubMed: 9773990]
3. Figueroa AA, Polley JW, Ko EW. Maxillary distraction for the management of cleft maxillary hypoplasia with a rigid external distraction system. *Semin Orthod.* 1999;5:46–51. [PubMed: 10371940]
4. Saltaji H, Major MP, Altalibi M, Youssef M, Flores-Mir C. Long-term skeletal stability after maxillary advancement with distraction osteogenesis in cleft lip and palate patients. *Angle Orthod.* 2012;82:1115–22. [PubMed: 22506512]
5. Iida S, Yagi T, Yamashiro T, Okura M, Takada K, Kogo M. Maxillary anterior segmental distraction osteogenesis with the dynaform system for severe maxillary retrusion in cleft lip and palate. *Plast Reconstr Surg.* 2007;120:508–16. [PubMed: 17632357]
6. Alkan A, Baş B, Ozer M, Bayram M, Yüzbasioğlu E. Maxillary anterior segmental advancement of hypoplastic maxilla in cleft patients by distraction osteogenesis: Report of 2 cases. *J Oral Maxillofac Surg.* 2008;66:126–32. [PubMed: 18083426]
7. Aikawa T, Haraguchi S, Tanaka S, Uematsu S, Ishibashi M, Kogo M, et al. Rotational movement of the anterior maxillary segment by hybrid distractor in patients with cleft lip and palate. *Oral Surg Oral Med Oral Pathol Oral Radiol Endod.* 2010;110:292–300. [PubMed: 20418128]
8. Bevilacqua RG, Ritoli EL, Kang C, Mabry K, Castiglione CL. Midmaxillary internal distraction osteogenesis: Ideal surgery for the mature cleft patient. *Plast Reconstr Surg.* 2008;121:1768–78. [PubMed: 18454002]
9. Rachmiel A, Aizenbud D, Peled M. Distraction osteogenesis in maxillary deficiency using a rigid external distraction device. *Plast Reconstr Surg.* 2006;117:2399–406. [PubMed: 16772948]

10. Suzuki EY, Motohashi N, Ohyama K. Longitudinal dento-skeletal changes in UCLP patients following maxillary distraction osteogenesis using RED system. *J Med Dent Sci.* 2004;51:27–33. [PubMed: 15137462]
11. Lo LJ, Hung KF, Chen YR. Blindness as a complication of Le Fort I osteotomy for maxillary distraction. *Plast Reconstr Surg.* 2002;109:688–98. [PubMed: 11818854]
12. Hochban W, Ganss C, Austermann KH. Long-term results after maxillary advancement in patients with clefts. *Cleft Palate Craniofac J.* 1993;30:237–43. [PubMed: 8452847]
13. Yamauchi K, Mitsugi M, Takahashi T. Maxillary distraction osteogenesis using Le Fort I osteotomy without intraoperative down-fracture. *Int J Oral Maxillofac Surg.* 2006;35:493–8. [PubMed: 16513321]
14. Molina F, Ortiz Monasterio F, de la Paz Aguilar M, Barrera J. Maxillary distraction: Aesthetic and functional benefits in cleft lip-palate and prognathic patients during mixed dentition. *Plast Reconstr Surg.* 1998;101:951–63. [PubMed: 9514327]
15. Kanno T, Mitsugi M, Hosoe M, Sukegawa S, Yamauchi K, Furuki Y. Long-term skeletal stability after maxillary advancement with distraction osteogenesis in nongrowing patients. *J Oral Maxillofac Surg.* 2008;66:1833–46. [PubMed: 18718390]
16. Nadjmi N, Schutyser F, Van Erum R. Trans-sinusal maxillary distraction for correction of midfacial hypoplasia: Long-term clinical results. *Int J Oral Maxillofac Surg.* 2006;35:885–96. [PubMed: 16965902]
17. Suzuki EY, Suzuki B. A simple mechanism for measuring and adjusting distraction forces during maxillary advancement. *J Oral Maxillofac Surg.* 2009;67:2245–53. [PubMed: 19761920]
18. Chua HD, Hägg MB, Cheung LK. Cleft maxillary distraction versus orthognathic surgery - Which one is more stable in 5 years? *Oral Surg Oral Med Oral Pathol Oral Radiol Endod.* 2010;109:803–14. [PubMed: 20299247]
19. Ahn JG, Figueroa AA, Braun S, Polley JW. Biomechanical considerations in distraction of the osteotomized dentomaxillary complex. *Am J Orthod Dentofacial Orthop.* 1999;116:264–70. [PubMed: 10474097]
20. Kusnoto B, Figueroa AA, Polley JW. Radiographic evaluation of bone formation in the pterygoid region after maxillary distraction with a rigid external distraction (RED) device. *J Craniofac Surg.* 2001;12:109–17. [PubMed: 11314619]
21. Alkan A, Inal S, Ba° B, Ozer M. Incomplete mobilization of the maxilla resulting in failed maxillary distraction: A case report. *Oral Surg*

- Oral Med Oral Pathol Oral Radiol Endod. 2007;104:e5–11. [PubMed: 17942333]
22. Wenghoefer M, Martini M, Nadjmi N, Schutyser F, Jagtman AK, Bergé S. Trans-sinusoidal maxillary distraction in three cleft patients. *Int J Oral Maxillofac Surg.* 2006;35:954–60. [PubMed: 17014993]
23. Dolanmaz D, Esen A, Emlik D, Candirli C, Kalayci A, Çiçekcibağcı A. Comparison of two different approaches to the pterygomaxillary junction in Le Fort I osteotomy. *Oral Surg Oral Med Oral Pathol Oral Radiol Endod.* 2008;106:e1–5. [PubMed: 18602283]
24. Block MS, Cervini D, Chang A, Gottsegen GB. Anterior maxillary advancement using tooth-supported distraction osteogenesis. *J Oral Maxillofac Surg.* 1995;53:561–5. [PubMed: 7722725]
25. Figueroa AA, Polley JW, Figueroa AL. Introduction of a new removable adjustable intraoral maxillary distraction system for correction of maxillary hypoplasia. *J Craniofac Surg.* 2009;20(Suppl 2):1776–86. [PubMed: 19816350]
26. Feng Y, Fang B, Shen G, Xia Y, Lou X. Reconstruction of partial maxillary defect with intraoral distraction osteogenesis assisted by miniscrew implant anchorages. *Oral Surg Oral Med Oral Pathol Oral Radiol Endod.* 2010;110:e1–7.
27. Baek SH, Lee JK, Lee JH, Kim MJ, Kim JR. Comparison of treatment outcome and stability between distraction osteogenesis and LeFort I osteotomy in cleft patients with maxillary hypoplasia. *J Craniofac Surg.* 2007;18:1209–15. [PubMed: 17912117]
28. Swennen G, Dujardin T, Goris A, De Mey A, Malevez C. Maxillary distraction osteogenesis: A method with skeletal anchorage. *J Craniofac Surg.* 2000;11:120–7. [PubMed: 11314124]
29. Harada K, Sato M, Omura K. Long-term maxillomandibular skeletal and dental changes in children with cleft lip and palate after maxillary distraction. *Oral Surg Oral Med Oral Pathol Oral Radiol Endod.* 2006;102:292–9. [PubMed: 16920536]
30. Umstadt HE. Maxillary advancement in cleft patients by means of transantral distraction: Development of a new type of distraction device and pilot study of its clinical application. *Plast Reconstr Surg.* 2005;116:591–8. [PubMed: 16079695]

Figures and Tables

table-wrap mode="anchored" t5

Table 1

Patient	Gender	Age (year)	Cleft type	Surgical procedure	Amount of advancement (mm)	Activation period (day)	Rate of movement (mm/d)	Max force (N)
1	M	18	UCLP	DF	7.9	11	0.72	15.3
2	M	22	UCLP	DF	14.1	18	0.78	23.6
3	M	24	UCLP	DF	10.6	11	0.96	16.9
4	M	26	UCLP	DF	9.4	10	0.94	16.1
5	F	21	UCLP	DF	8.6	10	0.86	16.7
6	F	15	BCLP	DF	9.6	10	0.96	16.7
7	M	21	BCLP	NDF	7.5	21	0.36	35.6
8	M	22	UCLP	NDF	4.2	14	0.3	30.2

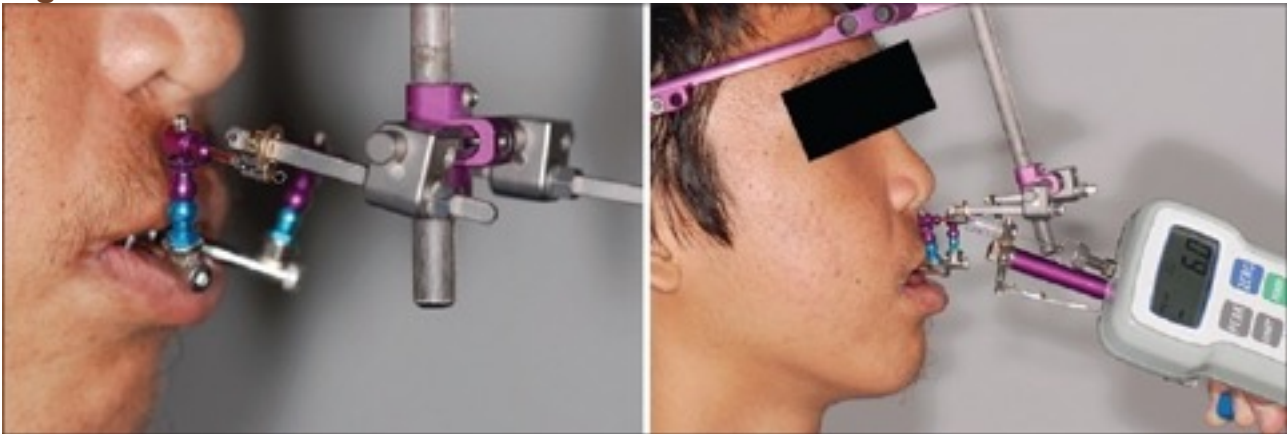
UCLP=Unilateral cleft lip and palate; BCLP=Bilateral cleft lip and palate; DF=Down-Fracture; NDF=Non-Down-Fracture

caption a7

Patient data and distraction outcomes

fig mode="anchored" f5

Figure 1

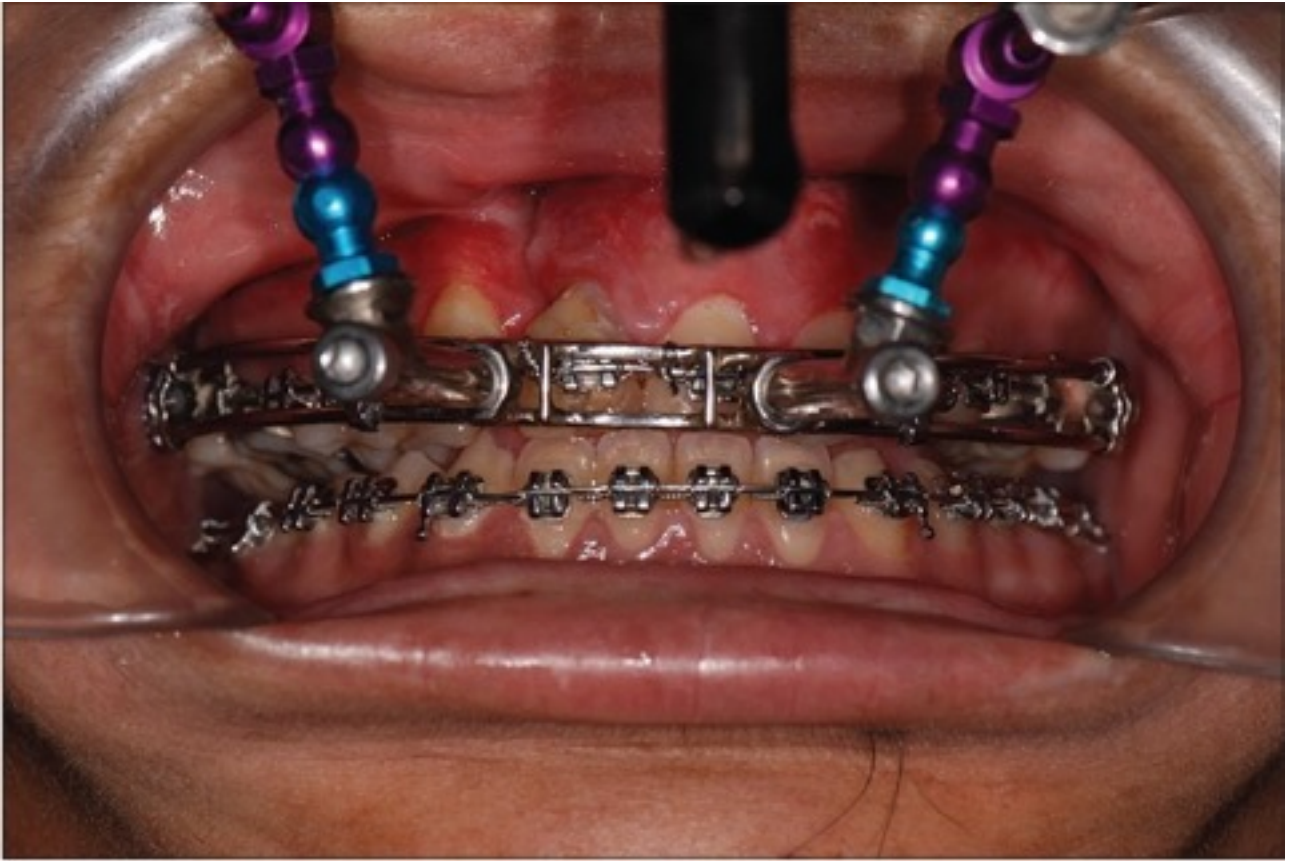

caption a7

Rigid external distraction system combined with a twin-track distractor connected to the dentition

fig mode="anchored" f5

Figure 2

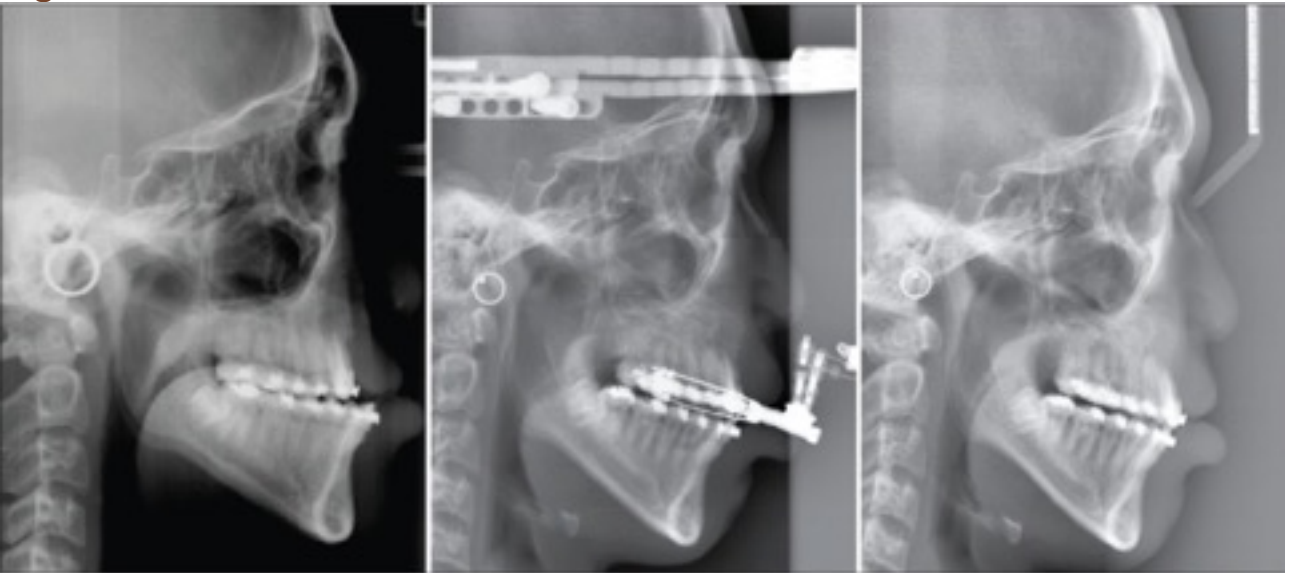


caption a7

Intraoral picture of the twin-track distraction

fig mode="anchored" f5

Figure 3

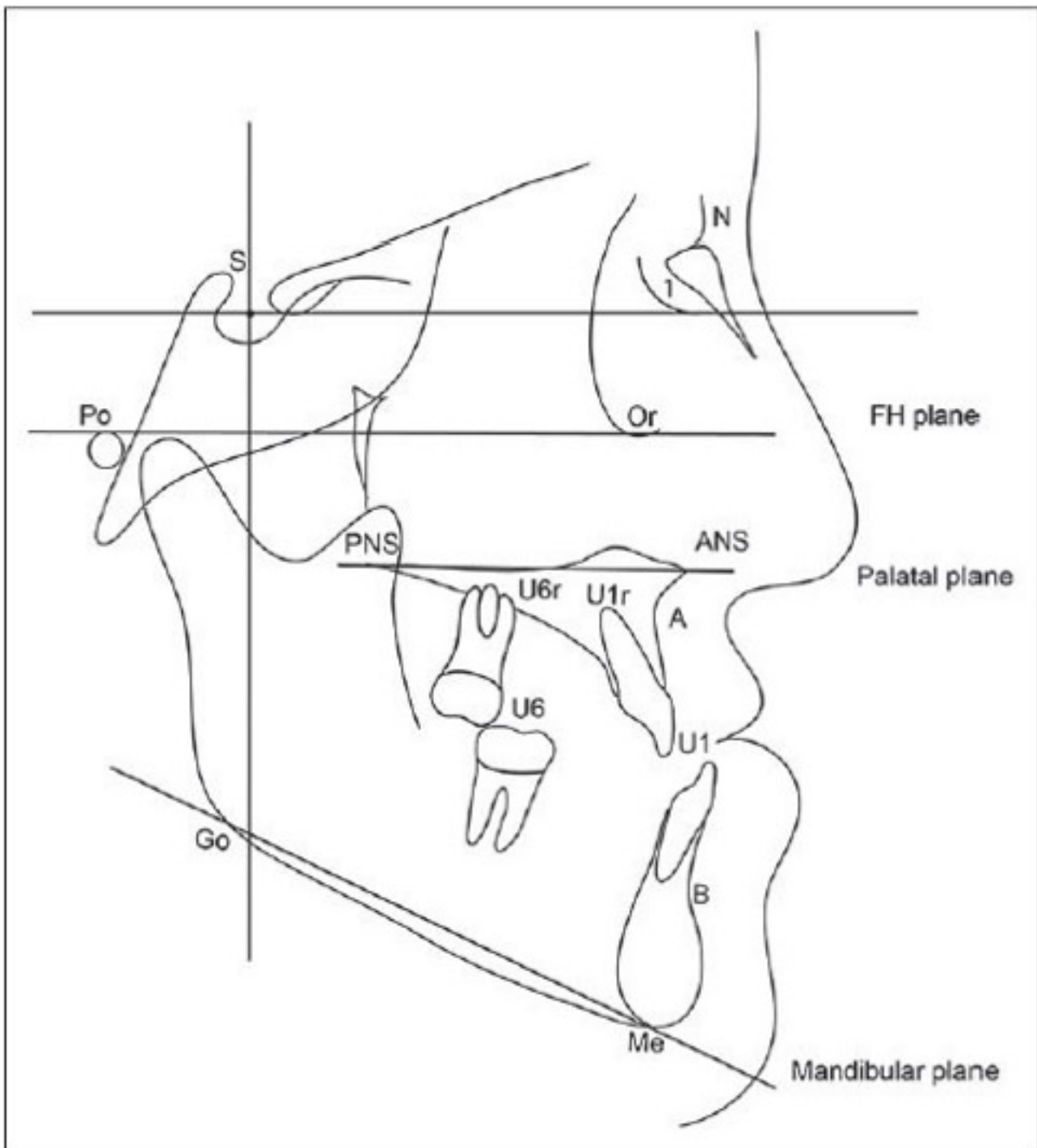


caption a7

Evaluation of maxillary distraction osteogenesis was performed with lateral cephalograms

fig mode="anchored" f5

Figure 4a

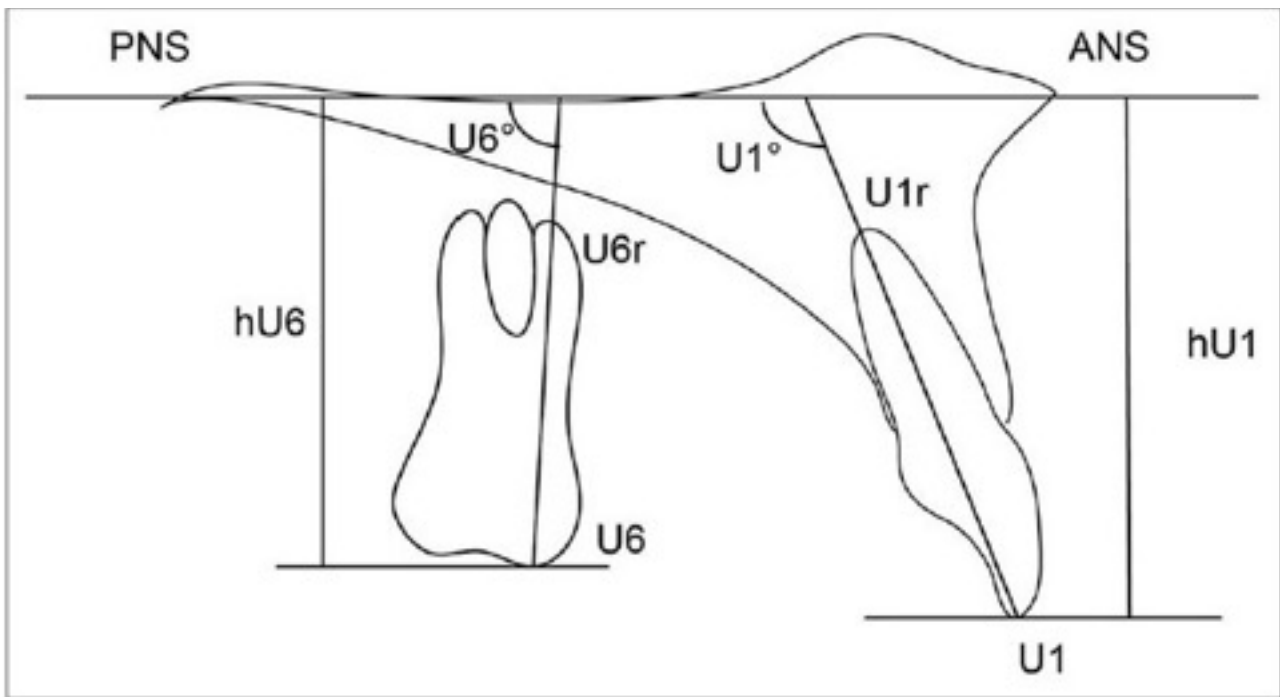


caption a7

Cephalometric landmarks and reference planes. Sella (S); nasion (N); orbitale (Or); porion (Po); anterior nasal spine (ANS); posterior nasal spine (PNS); Point A (A); Point B (B); menton (Me); gonion (Go); upper central incisor edge (U1); apex of upper central incisor (U1r); midpoint of upper first molar crown (U6); mesial root apex of upper first molar (U6r); Frankfort horizontal (FH) plane; palatal plane and mandibular plane

fig mode="anchored" f5

Figure 4b



caption a7

Measurement of dento-alveolar changes: Vertical distance of the upper incisor edge from the palatal plane (hU1); vertical distance of the medial buccal crown top of upper first molar from the palatal plane (hU6); inclination of the upper central incisor (U1°) and first molar (U6°) relative to the palatal plane

table-wrap mode="anchored" t5

Table 2

Variables	DF (n=6)				NDF (n=2)				Sig
	Median	Min	Max	Mean rank	Median	Min	Max	Mean rank	
Distalization protocol									
Latency (d)	4	4	5	26.0	4.5	4	5	10.0	NS
Activation period (d)	10.5	10	18	3.7	17.5	12	23	7.0	NS
Amount of activation (mm)	12.5	10	24	3.7	22.5	17	28	7.0	NS
Amount of movement (mm)	9.5	7.9	14.1	5.5	5.9	4.1	7.6	1.5	*
Movement : Activation	0.8	0.6	0.8	5.5	0.3	0.3	0.3	1.5	*
Rate of movement (mm/d)	0.9	0.7	1	5.5	0.4	0.3	0.4	1.5	*
Consolidation period (d)	25	24	33	4.2	27	25	29	5.5	NS
Dentoskeletal changes									
SNA (°)	7.5	5.3	9.8	5.5	4.4	3.5	5.2	1.5	*
SNB (°)	-1.3	-3.6	1.6	4.7	-1.7	-4	0.7	4.0	NS
ANB (°)	8	6.6	13.4	5.5	4.6	3.8	5.4	1.5	NS
Palatal plane (°)	2.5	-4.8	6.7	5.3	-8.3	-13.4	-3.2	2.0	NS
Mandibular plane (°)	1.1	0.6	2.1	3.5	3.4	2.6	4.1	7.5	*
U1 - PP (°)	-5.4	-10.8	1.2	3.6	12.6	1.2	24	7.3	NS
U1 - PP (mm)	0.8	-0.1	2.6	3.9	3.5	1.3	5.7	6.3	NS
U6 - PP (°)	-5.5	-11.5	-2	4.2	-1.7	-7.5	4.1	5.5	NS
U6 - PP (mm)	0	-4.1	1.7	4.0	1.3	0.5	2.1	6.0	NS
Distraction forces									
Maximum distraction force (N)	16.4	15.1	24.6	3.5	32.9	27.6	38.2	7.5	*
Force increment (N)	2.5	1.9	3.4	3.5	5.3	3.9	6.7	7.5	*
Force decay (N)	-1.8	-2.3	-1.3	4.7	-2.3	-3.2	-1.4	4.0	NS
Residual force at removal (N)	0.5	0.3	0.8	3.6	1.4	0.8	2	7.3	*

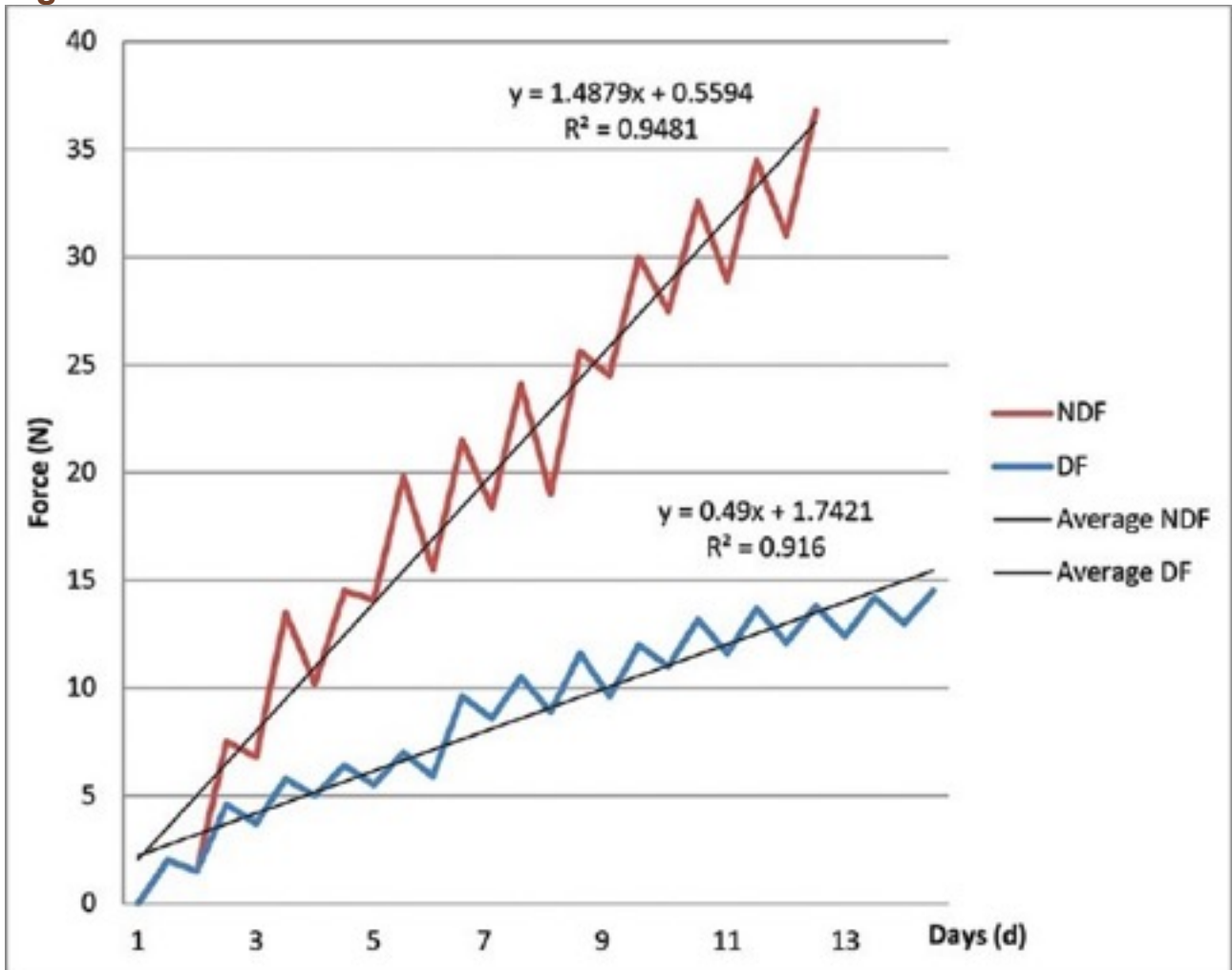
*P<0.05; NS=Not significant; DF=Down-fracture; NDF=Non-down-fracture; SNA=sella, Nasion, A point; SNB=Sella, nasion, B point; ANB=A Point, nasion, B Point; PP=Palatal plane

caption a7

Comparison between Down-fracture (DF) and Non-Down-Fracture (NDF) during the distractions period (T1 -T2)

fig mode="anchored" f5

Figure 5

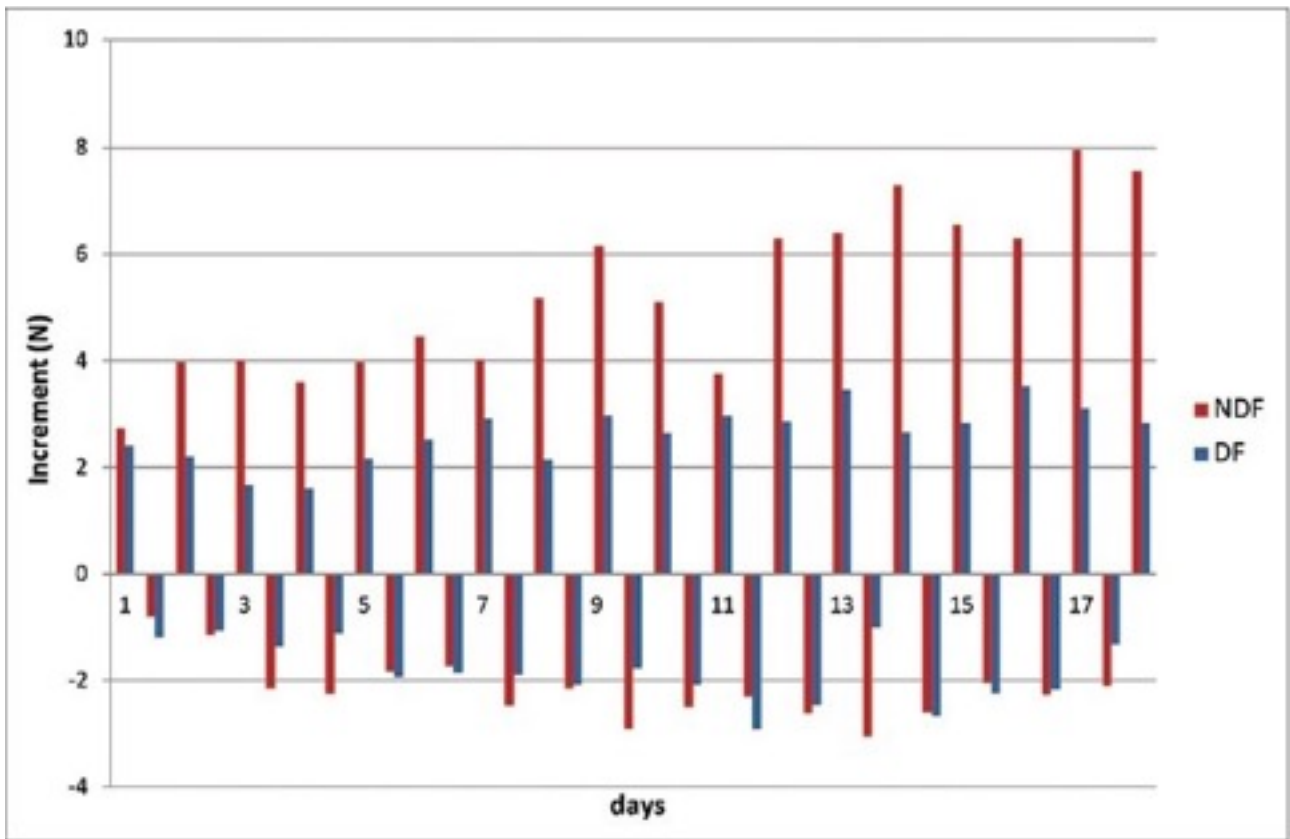


caption a7

Distraction force assessment between the down-fracture (DF) and non-DF groups

fig mode="anchored" f5

Figure 6



caption a7

Force increment between the down-fracture (DF) and non-DF groups

table-wrap mode="anchored" t5

Table 3

Variables	DF (n=6)				NDF (n=2)				Sig
	Median	Min	Max	Mean rank	Median	Min	Max	Mean rank	
Dentoskeletal changes									
Relapse (mm)	-1.6	-4.2	-1.2	5.5	-4.4	-5.2	-3.6	1.5	*
Relapse (%)	18%	13%	30%	5.5	0.72	-0.8	-0.65	1.5	*
SNA (°)	-1.3	-2.6	-0.2	5.5	-5	-5.8	-4.2	1.5	*
SNB (°)	1.9	1.7	2.9	4.5	1.5	-1.6	4.6	4.5	NS
ANB (°)	-3.4	-4.9	-2.7	4.5	-5.7	-8.8	-2.6	4.5	NS
Palatal plane (°)	-2.4	-3.6	-1.8	3.5	7.8	4.5	11	7.5	*
Mandibular plane (°)	-1.8	-2.6	-1.2	4.8	-2.8	-4.2	-1.4	3.5	NS
U1 - PP (°)	6.3	5.4	7.8	5.3	1.6	-1.2	4.4	2.0	NS
U1 - PP (mm)	-0.2	-1.5	1.4	4.2	-0.1	-0.2	0.1	5.5	NS
U6 - PP (°)	9.1	8.2	15	4.5	13.6	7.4	19.8	4.5	NS
U6 - PP (mm)	2.1	0.8	2.6	4.9	1.5	1	2	3.3	NS

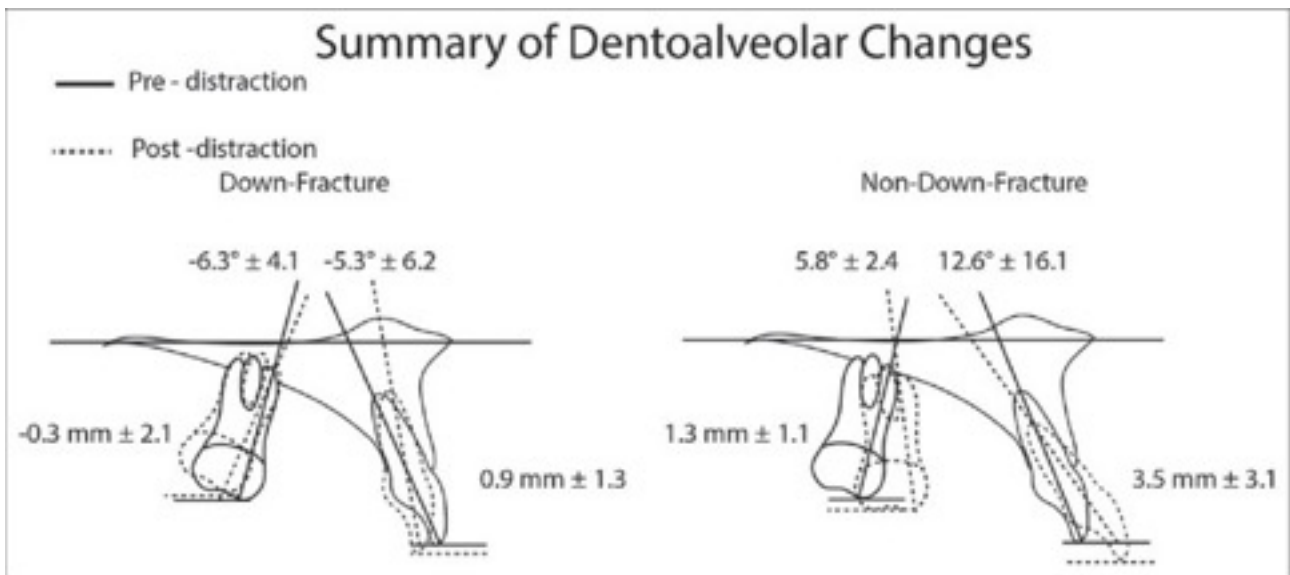
* $P < 0.05$; NS=Not significant; DF=Down-fracture; NDF=Non-down-fracture; SNA=Sella, nasion, A point; SNB=Sella, nasion, B point; ANB=A point, nasion, B point; PP=Palatal plane

caption a7

Comparison between Down-fracture (DF) and Non-Down-Fracture (NDF) during the follow-up period (T2 -T3)

fig mode="anchored" f5

Figure 7



caption a7

Comparison of dento-alveolar changes between the down-fracture (DF) and non-DF groups

post-content

Articles from Annals of Maxillofacial Surgery are provided here courtesy of **Medknow Publications**